

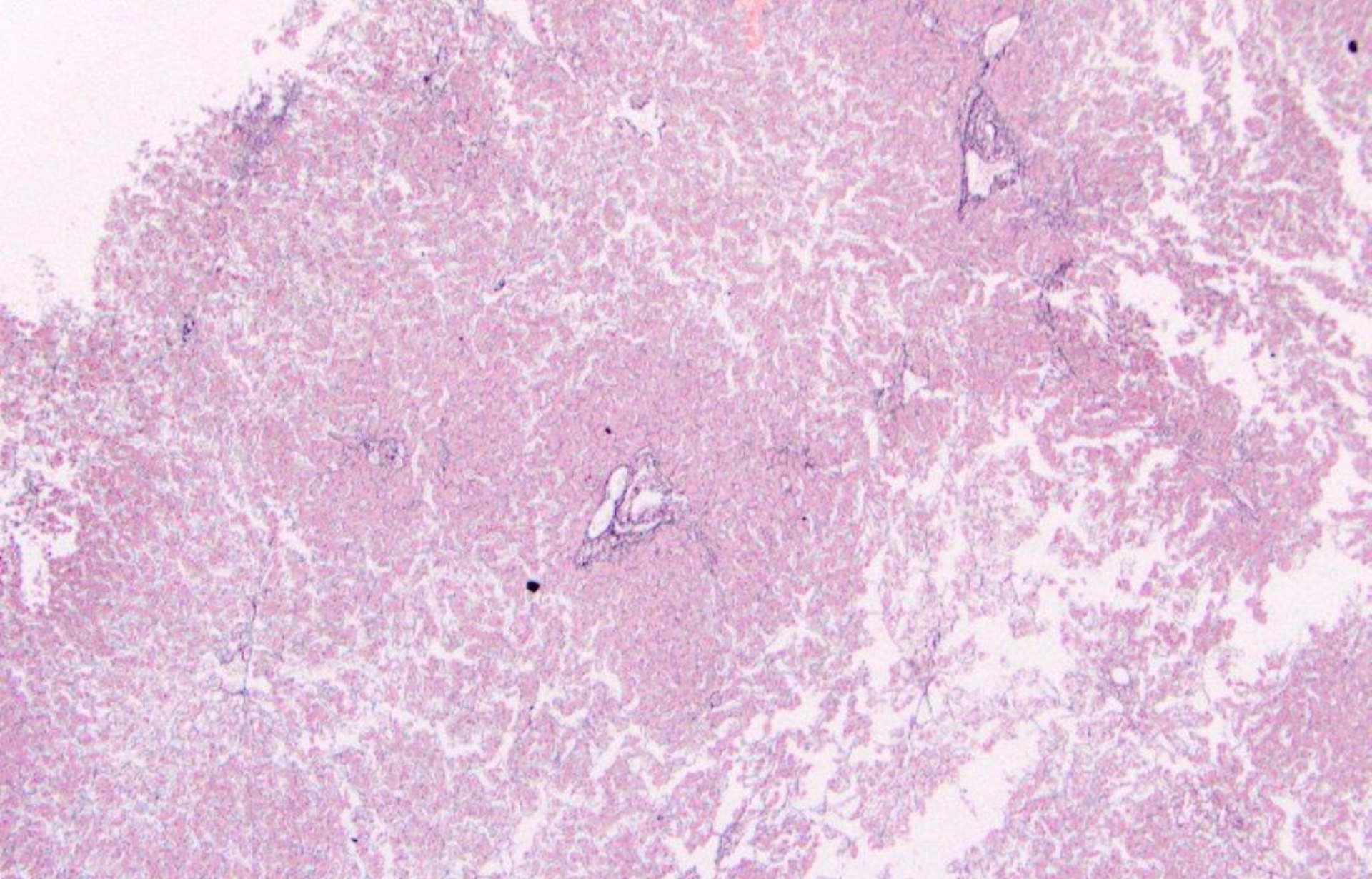
Oral Histopathology

Series 5 (special stains)

DAVID E. KLINGMAN, DMD

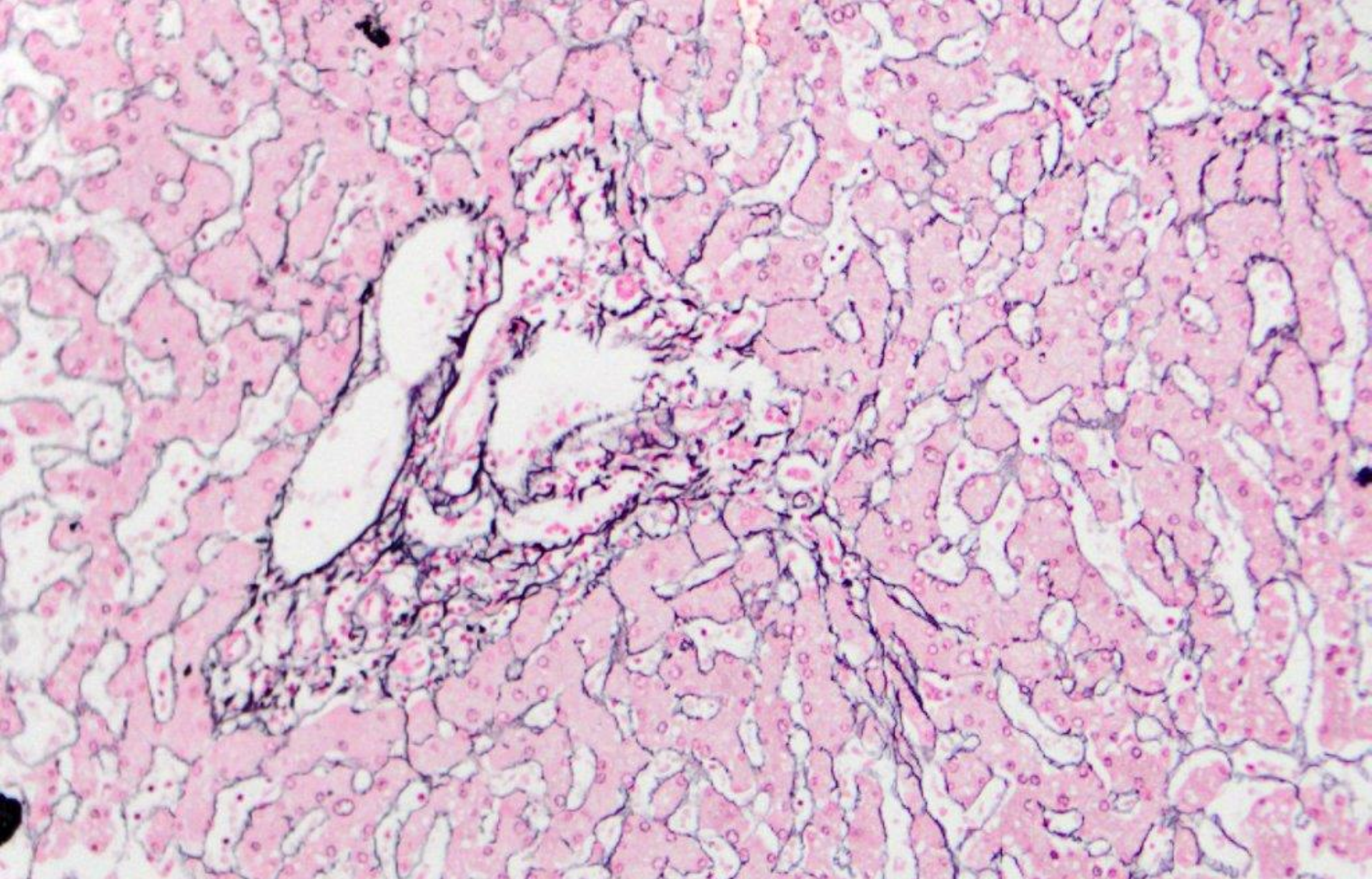
Diplomate, American Board of Oral and Maxillofacial Pathology

Diplomate, American Board of General Dentistry



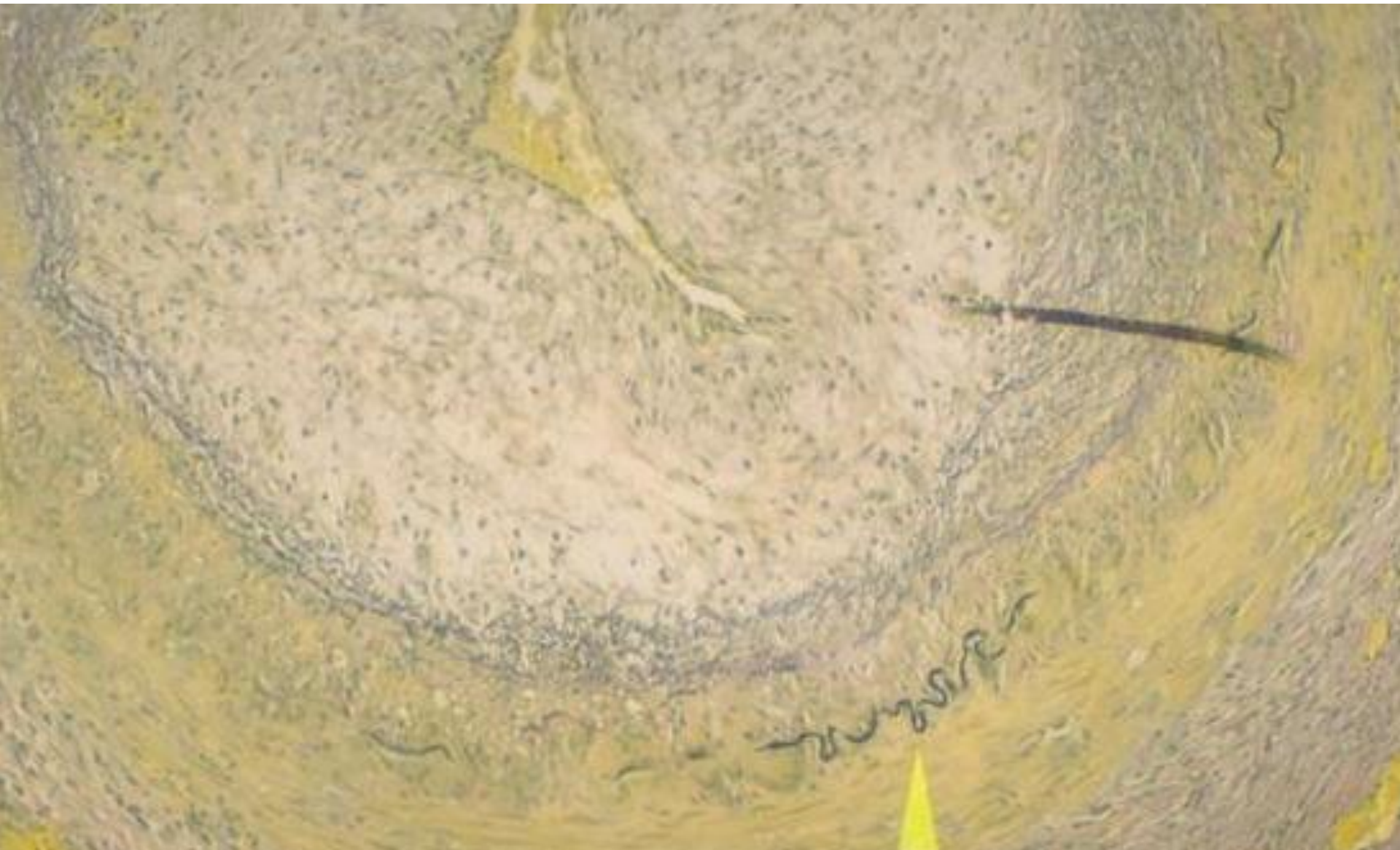
Reticulin stain:

Highlights reiculin fibers (which are argyrophilic) in parenchymal tissues in organs such as liver and spleen; demonstrates growth patterns of neoplasms



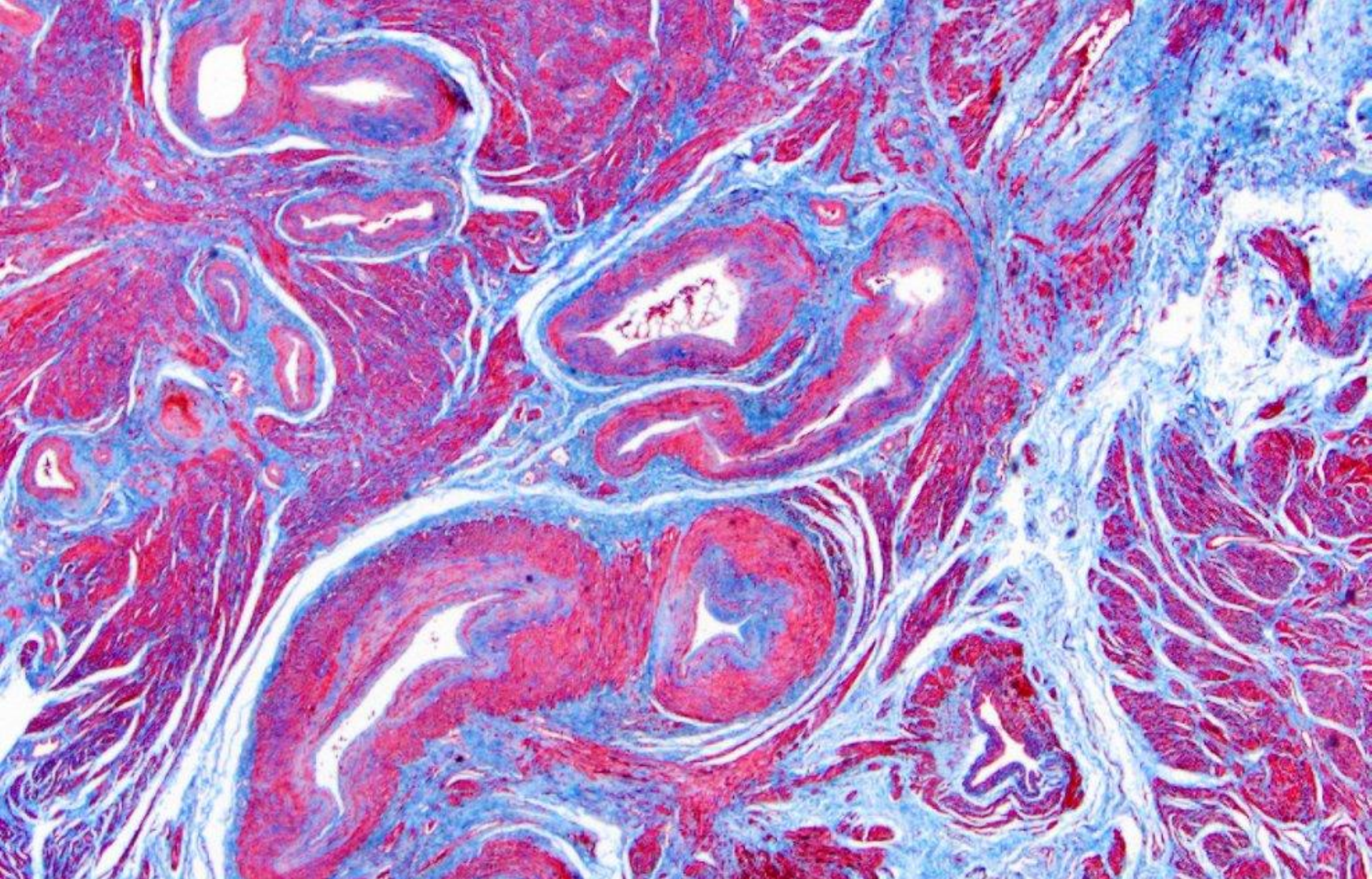
Reticulin stain:

Highlights reiculin fibers (which are argyrophilic) in parenchymal tissues in organs such as liver and spleen; demonstrates growth patterns of neoplasms



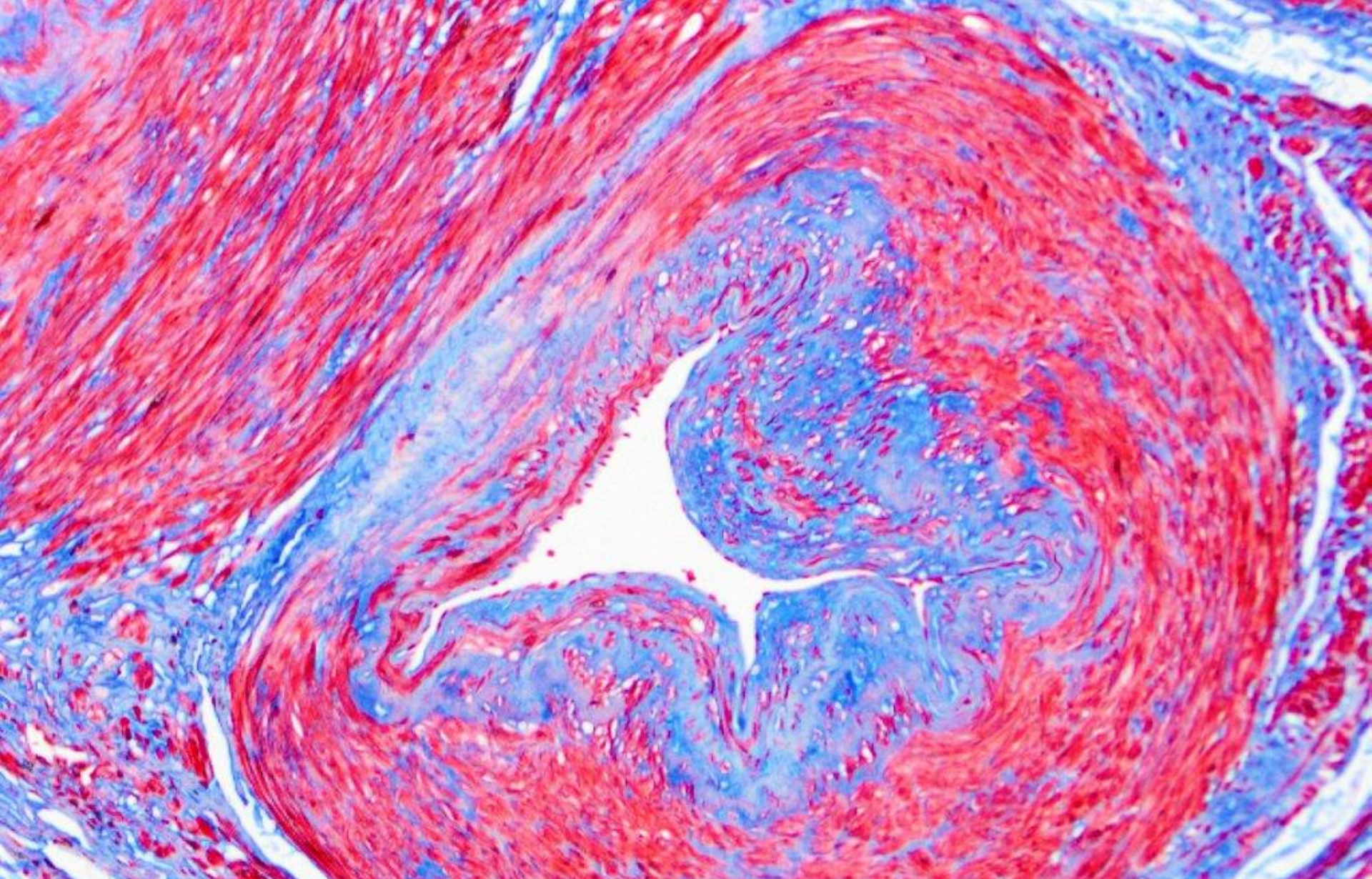
Elastic/Verhoeff's van Gieson stain:

Demonstrates atrophy of elastic tissue in cases of emphysema and thinning/loss of elastic fibers in arteriosclerosis, temporal arteritis and other vascular diseases



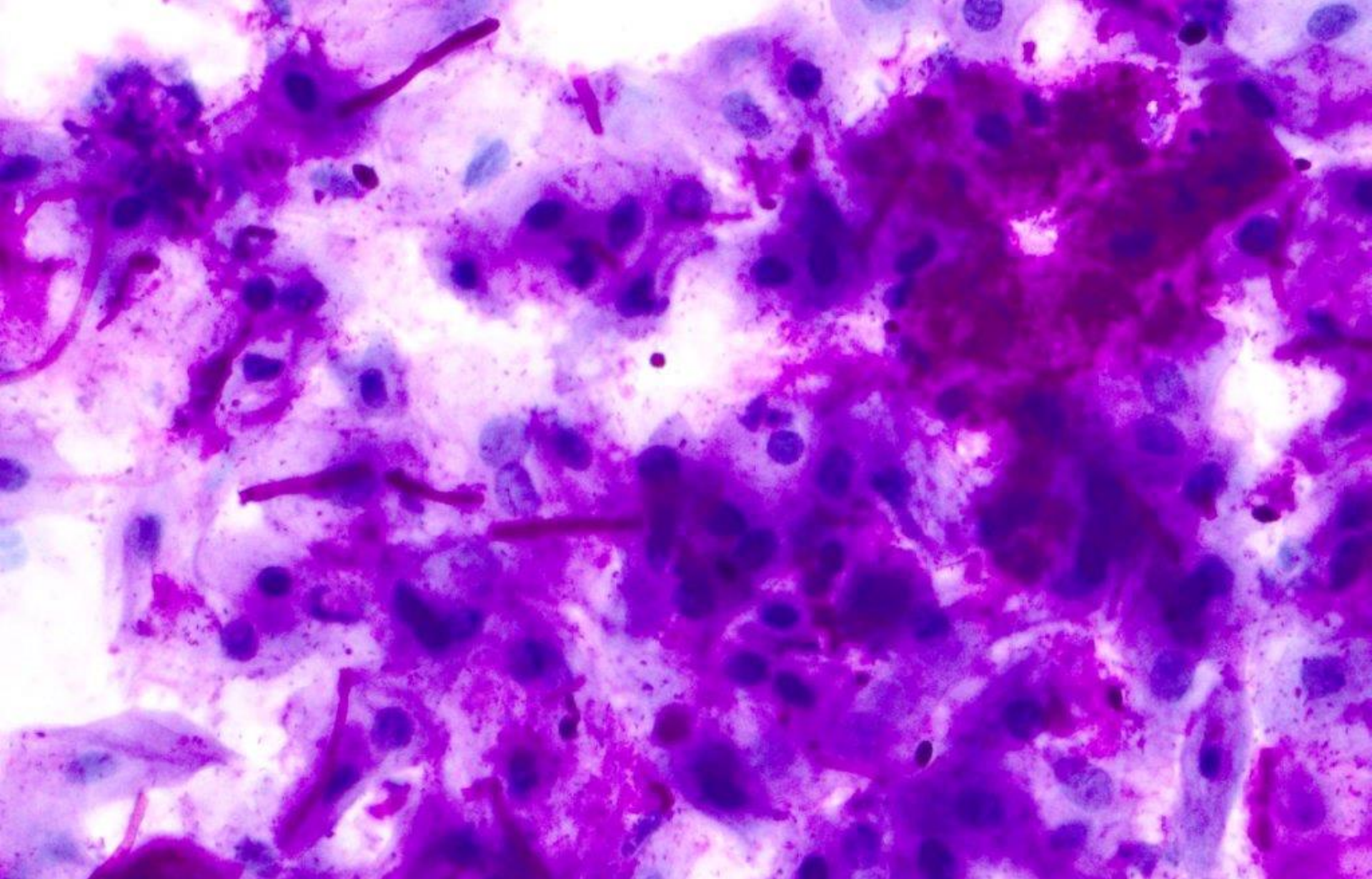
Masson's trichrome stain:

Differentiates collagen fibers from smooth muscle; routine stain for liver and kidney biopsy. Increases seen in collagen diseases (e.g. cirrhosis of liver)



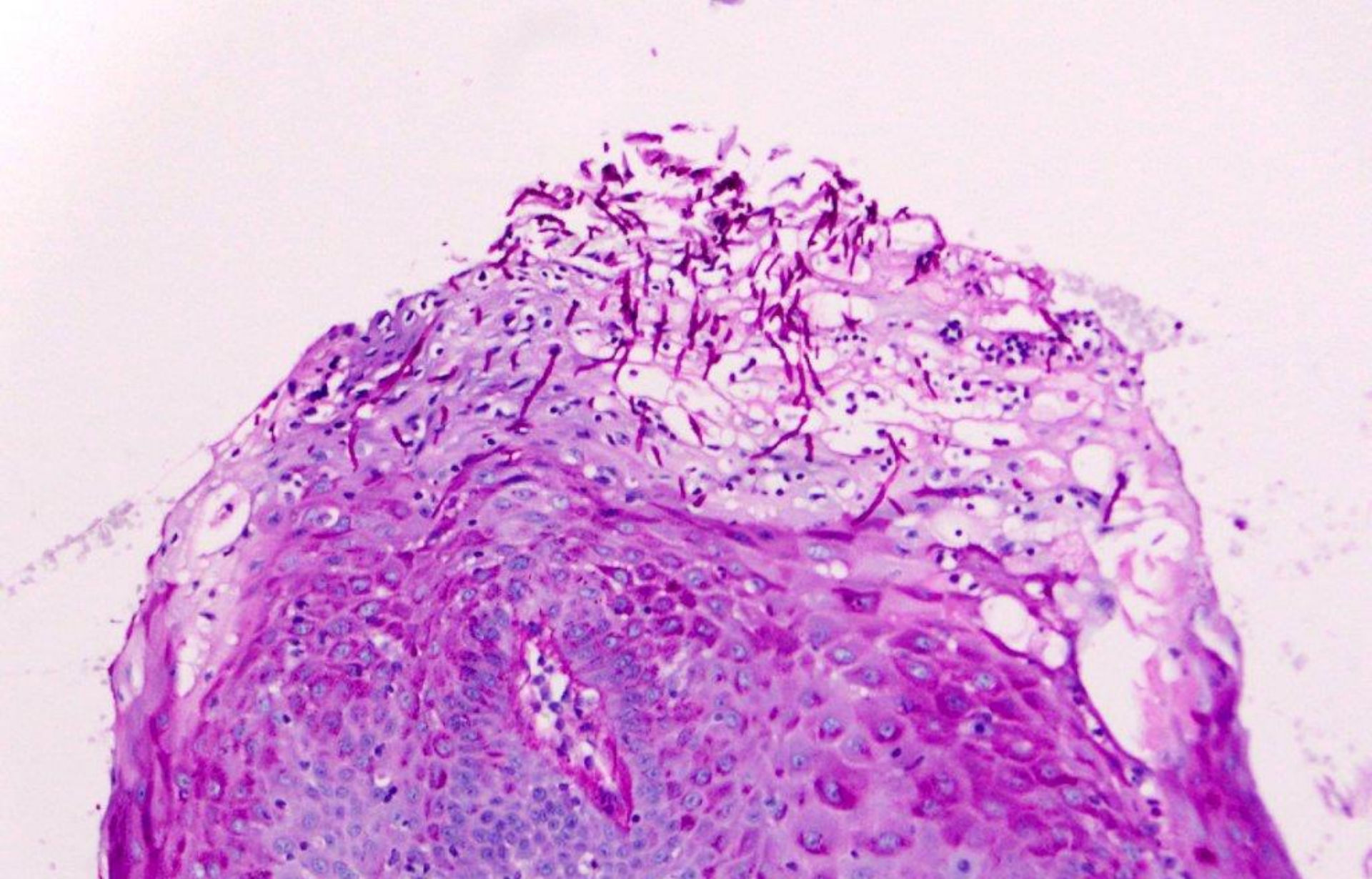
Masson's trichrome stain:

Differentiates collagen fibers from smooth muscle; routine stain for liver and kidney biopsy. Increases seen in collagen diseases (e.g. cirrhosis of liver)



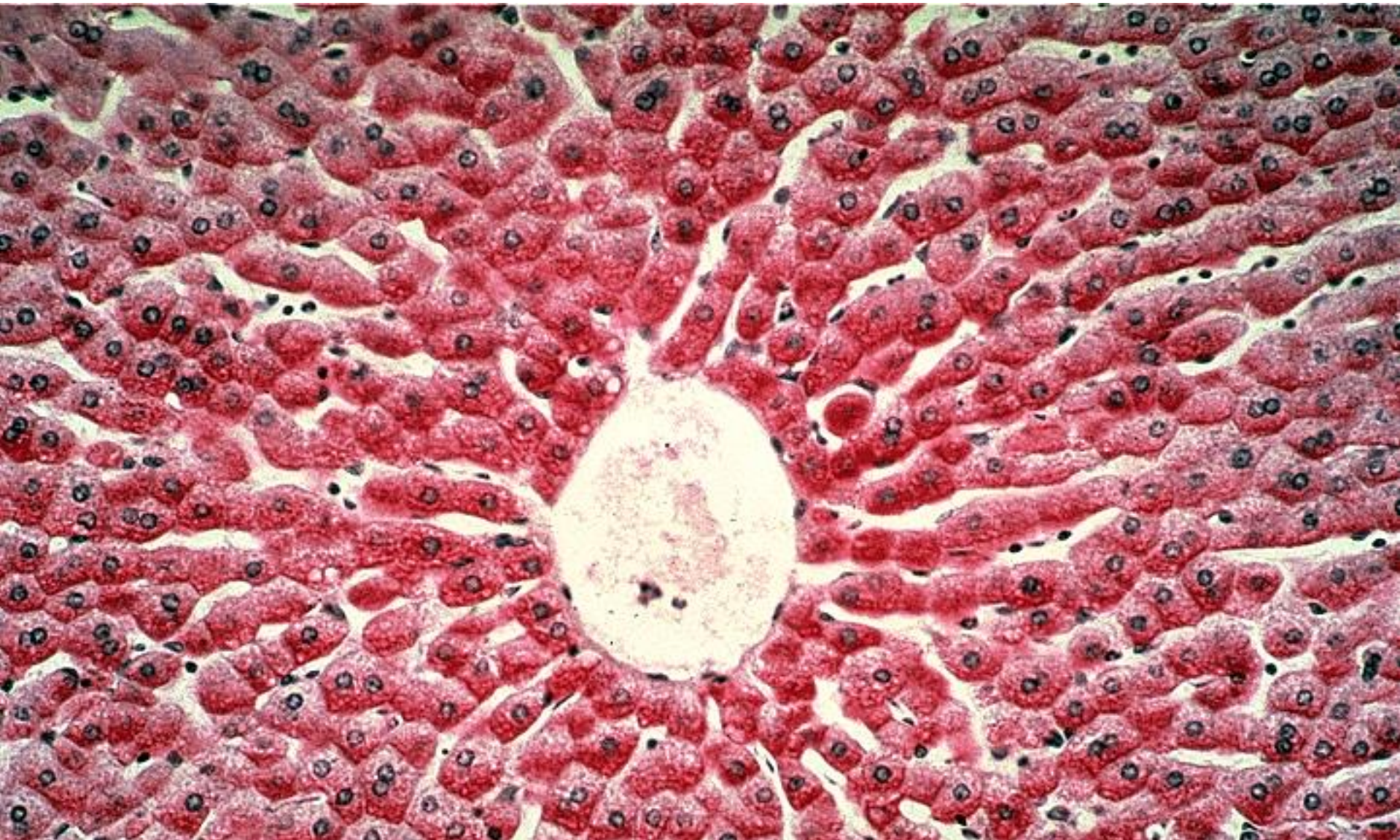
Periodic acid-Schiff stain (with or without diastase):

Demonstrates glycogen and polysaccharides; glycogen will be digested with diastase (diastase labile) versus mucins which will not digest (diastase resistant)



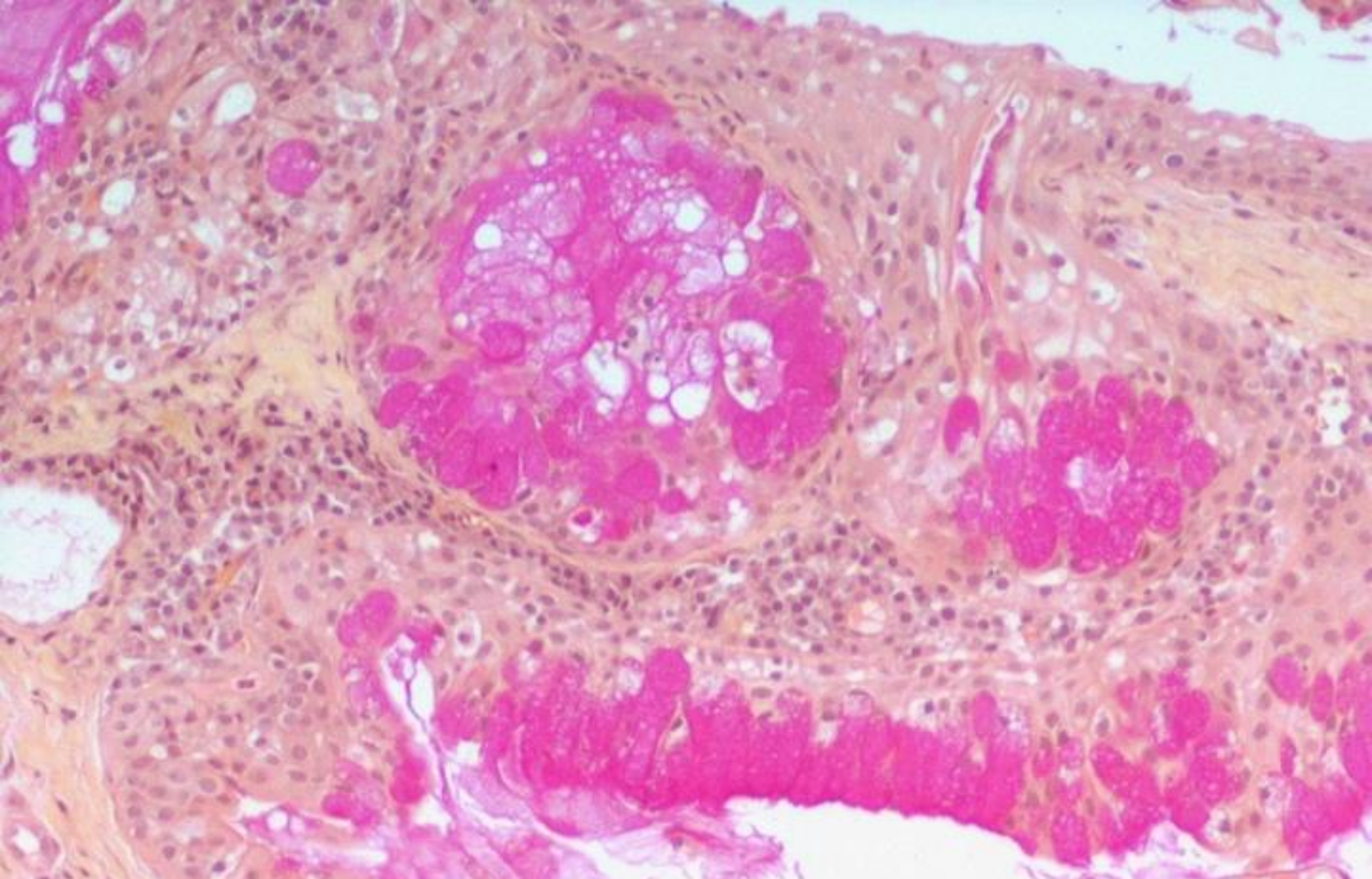
Periodic acid-Schiff stain (with or without diastase):

Demonstrates glycogen and polysaccharides; glycogen will be digested with diastase (diastase labile) versus mucins which will not digest (diastase resistant)



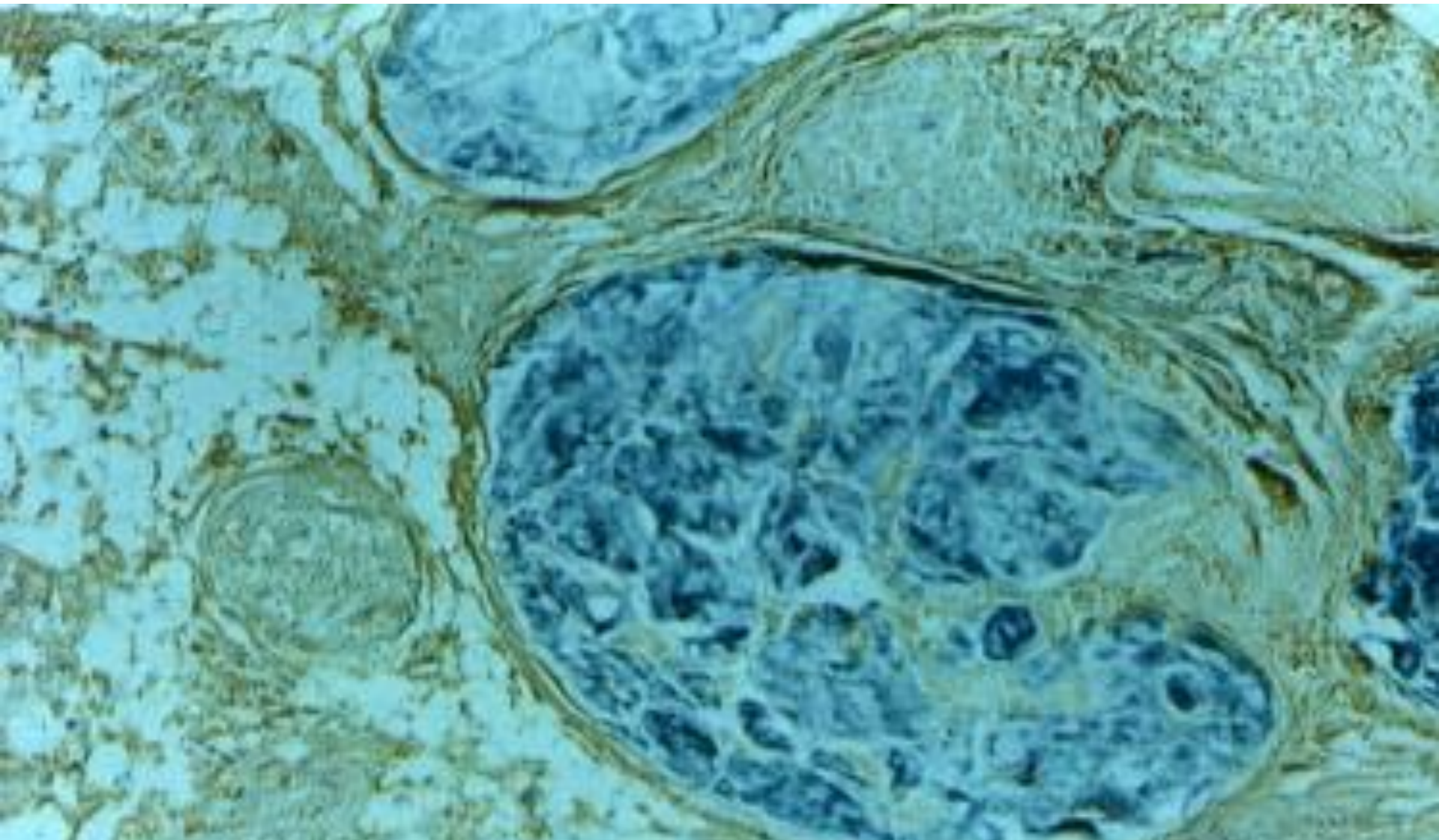
Best's carmine stain:

Red stain which highlights glycogen

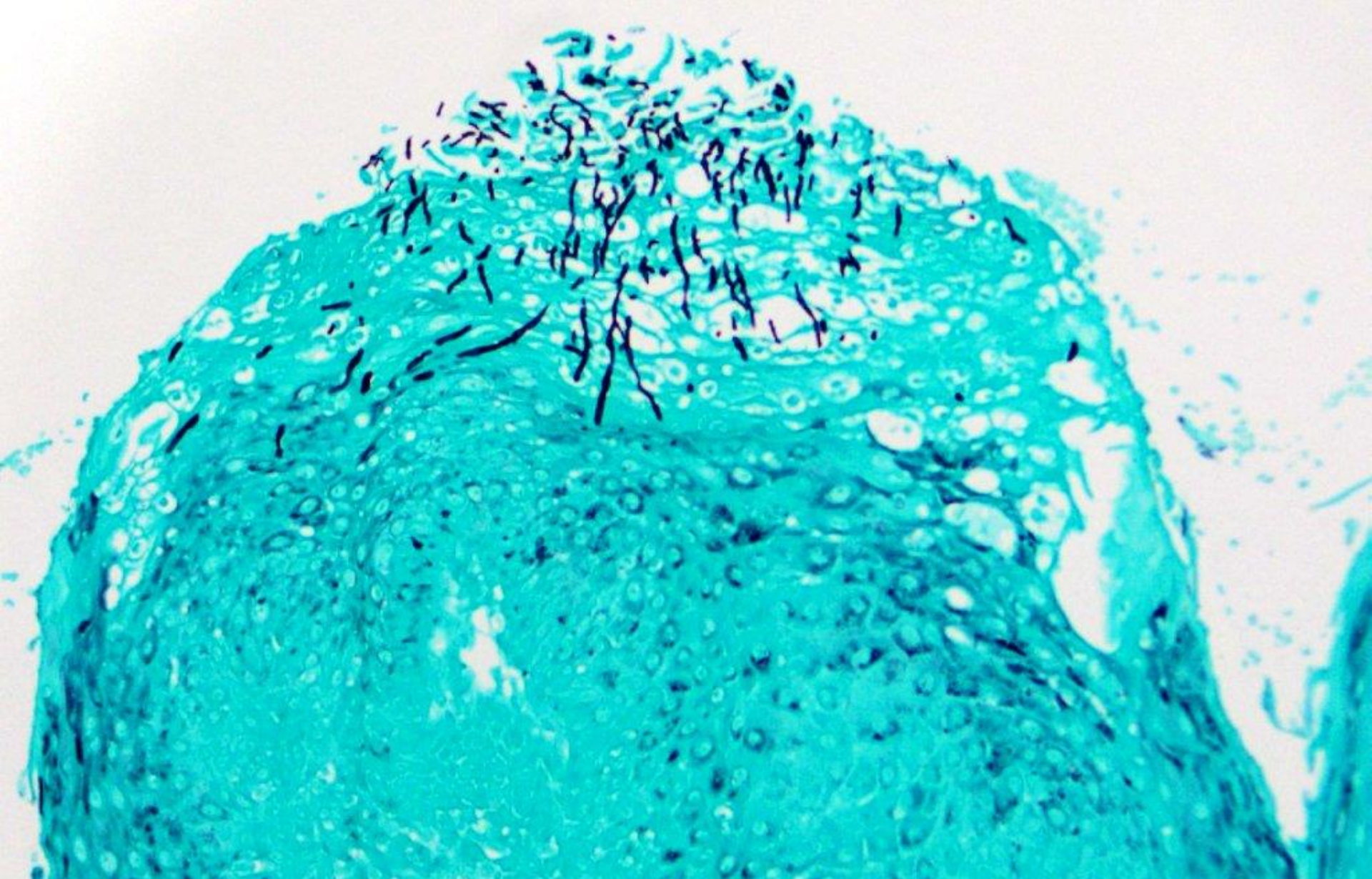


Mucicarmine stain:

Highlights bacteria (red); highlights mucin (useful in identifying mucus cells, for example, in mucoepidermoid carcinoma)

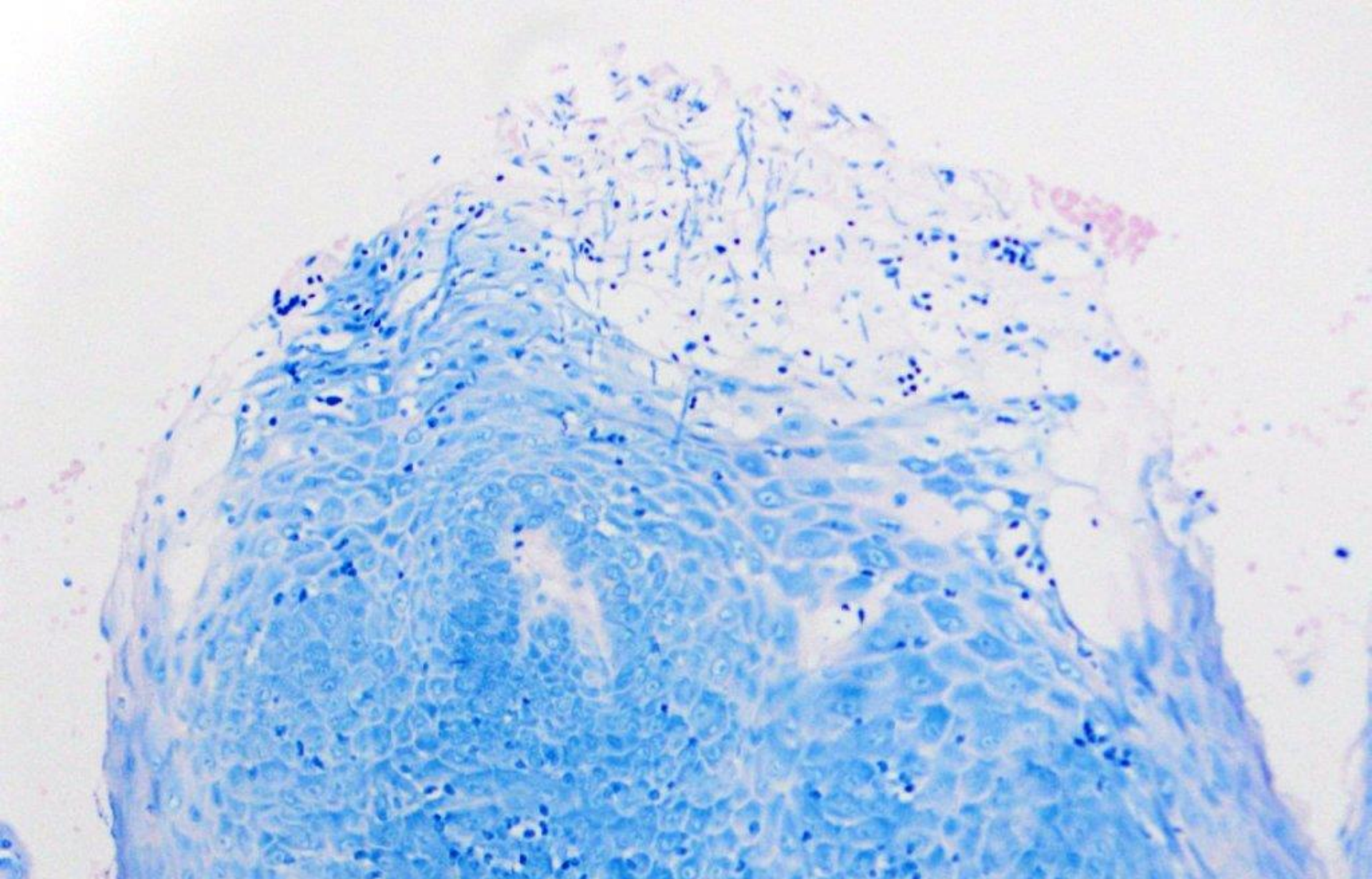


Alcian green stain:
Highlights cartilage



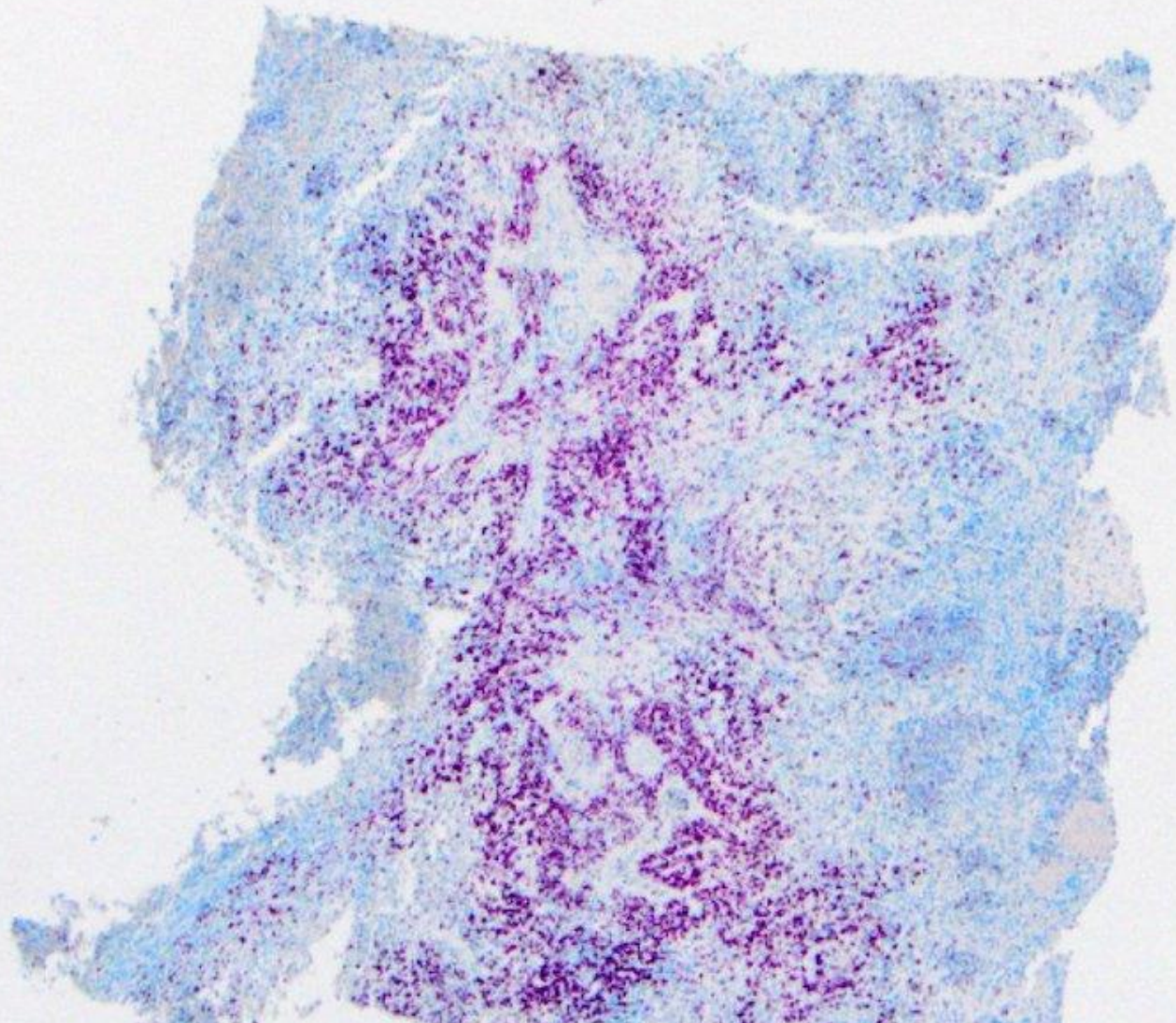
Grocott's methenamine silver stain:

Highlights the cell wall of microorganisms (useful for identifying fungal organisms)



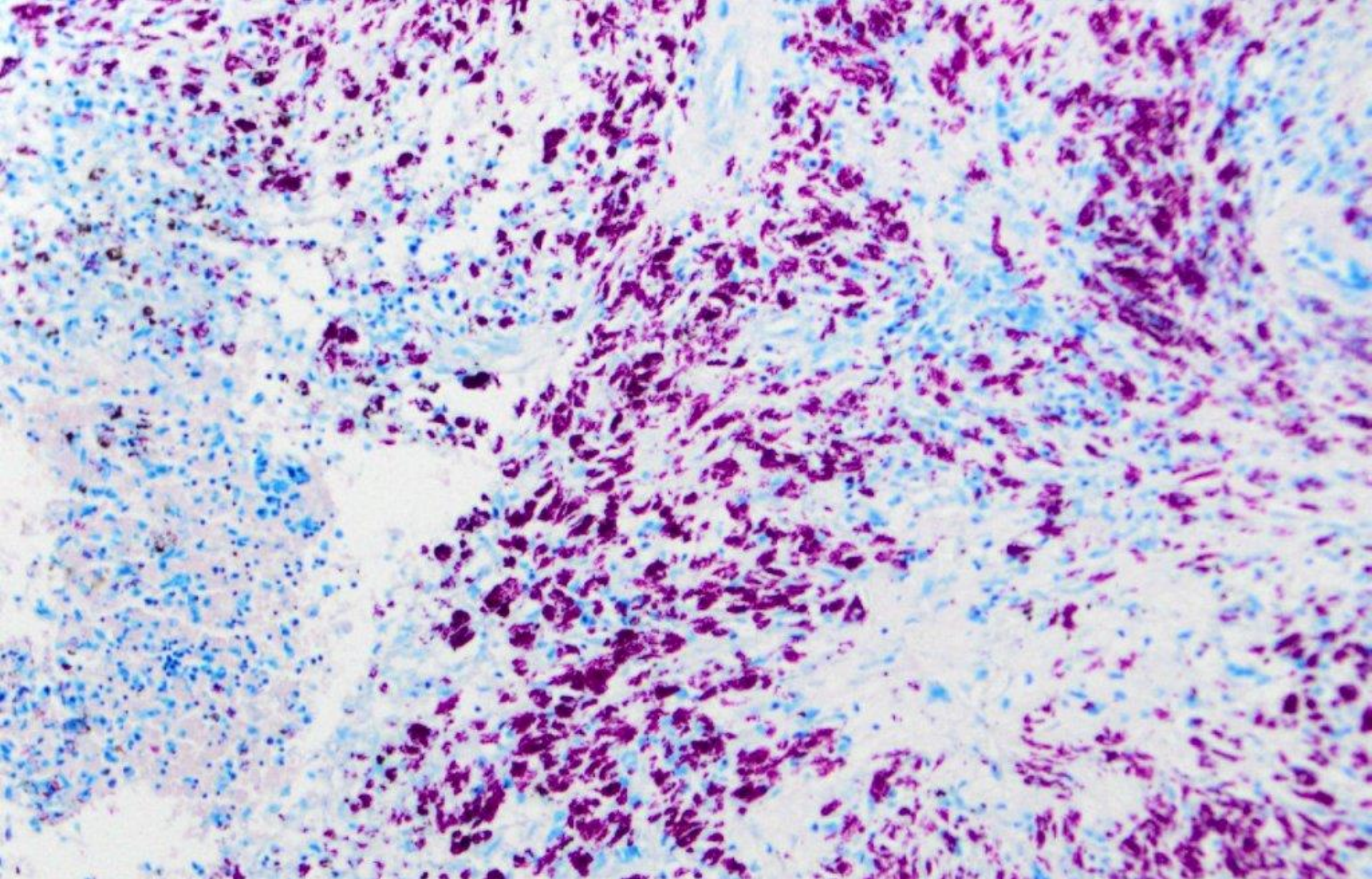
Acid fast stain:

Highlights certain bacteria, particularly *Mycobacterial* species



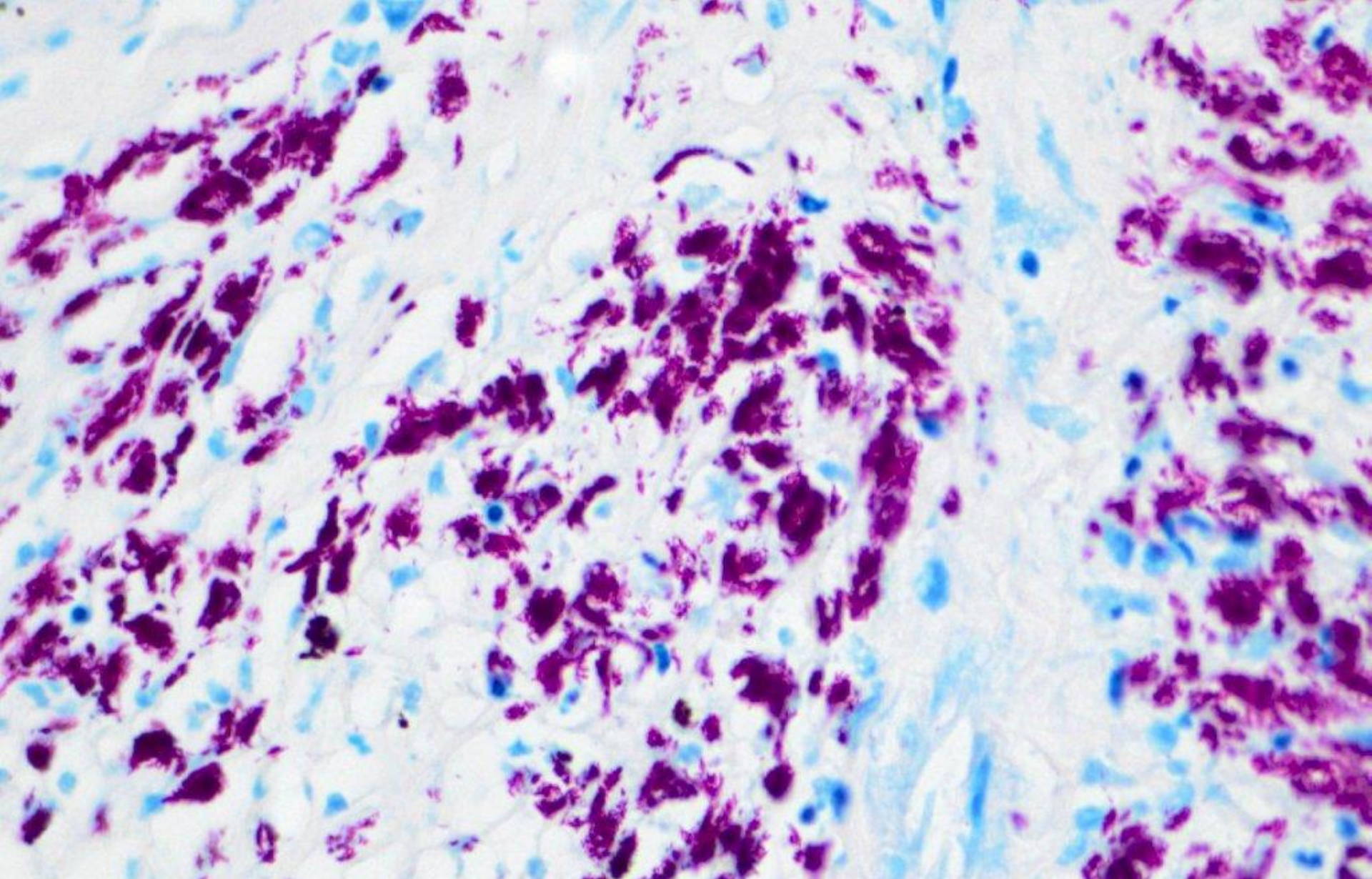
Acid fast stain:

Highlights certain bacteria, particularly *Mycobacterial* species



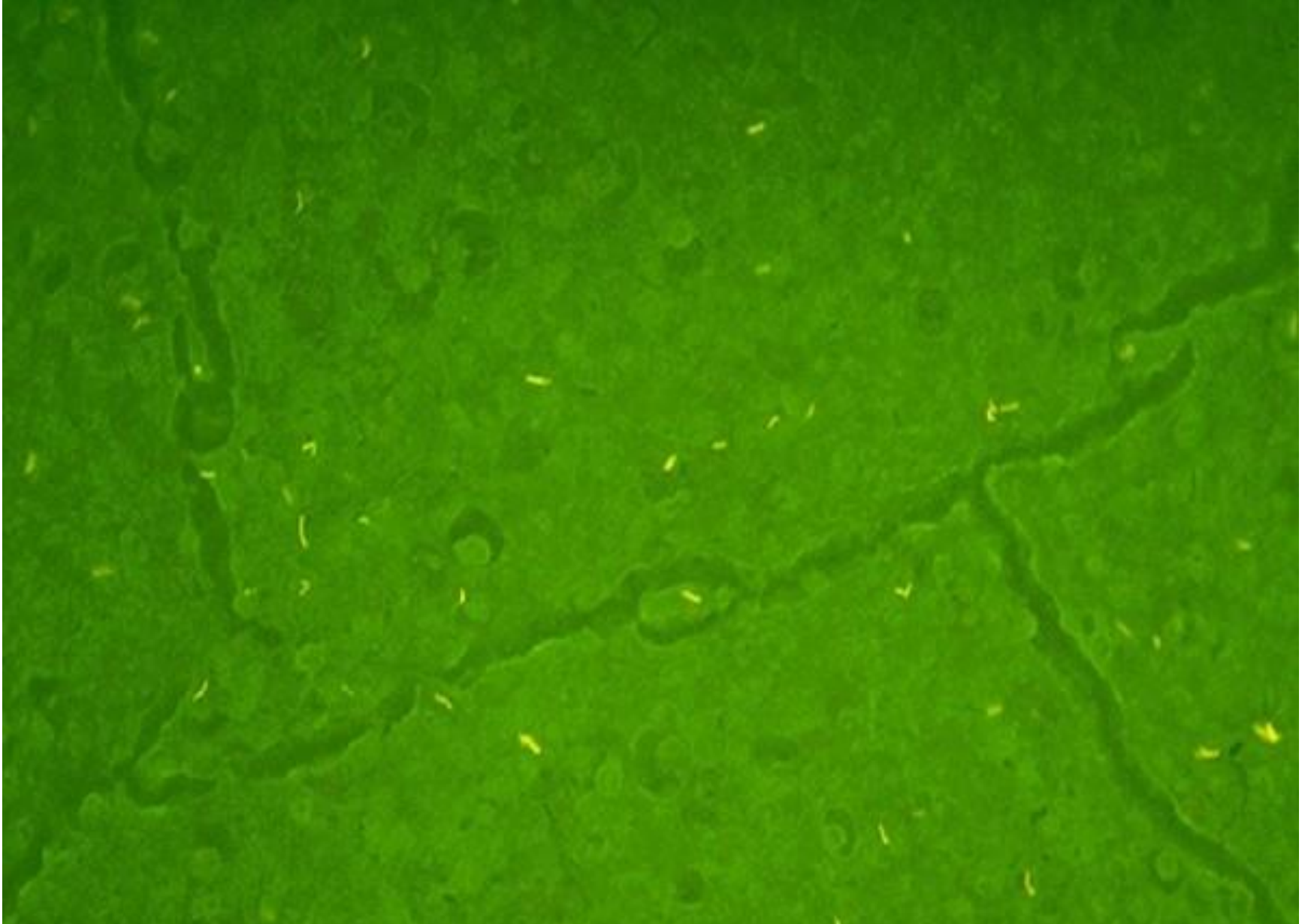
Acid fast stain:

Highlights certain bacteria, particularly *Mycobacterial* species



Acid fast stain:

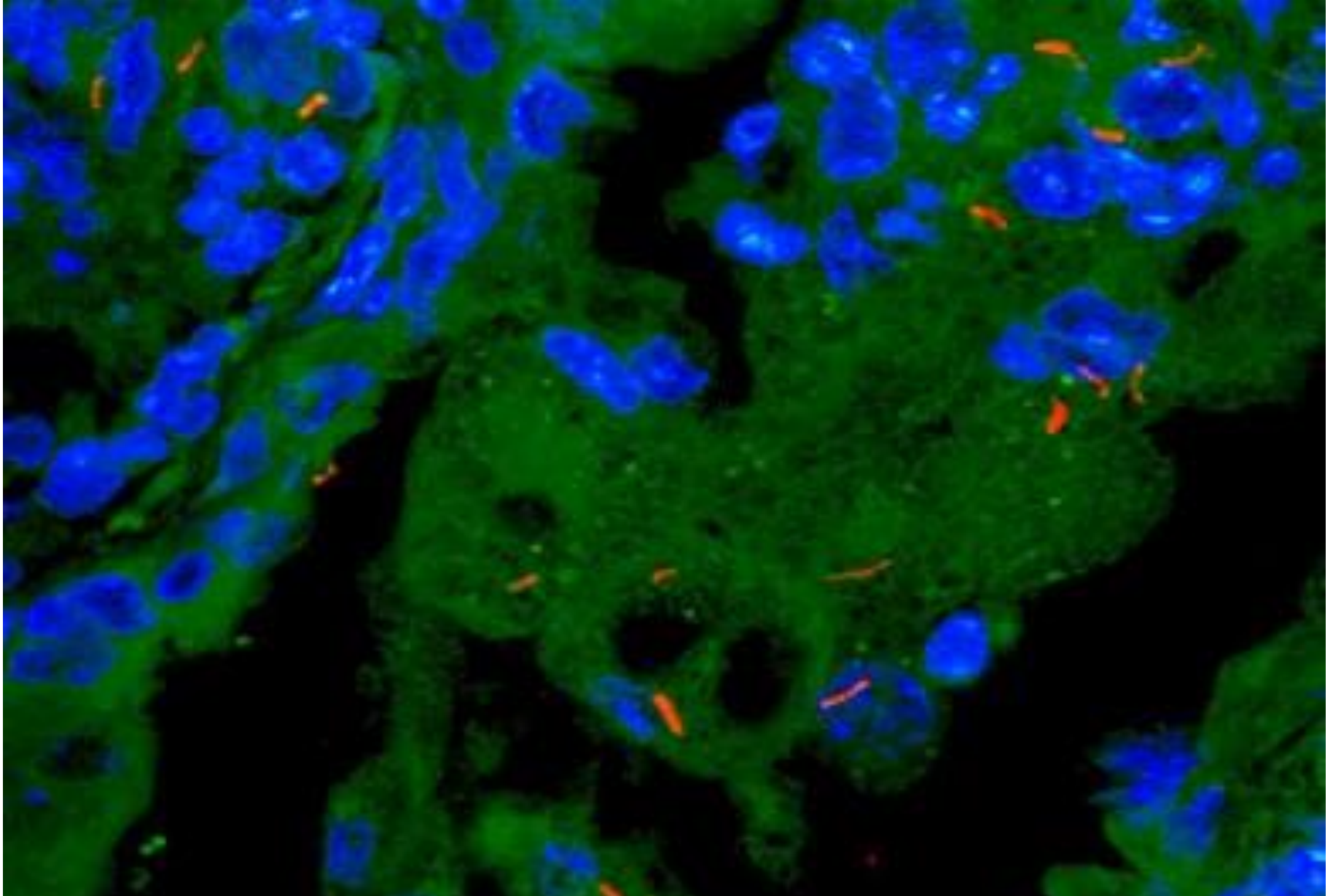
Highlights certain bacteria, particularly *Mycobacterial* species



Auramine rhodamine stain:

A fluorescence stain, used to highlight acid fast bacilli such as *Mycobacterium*

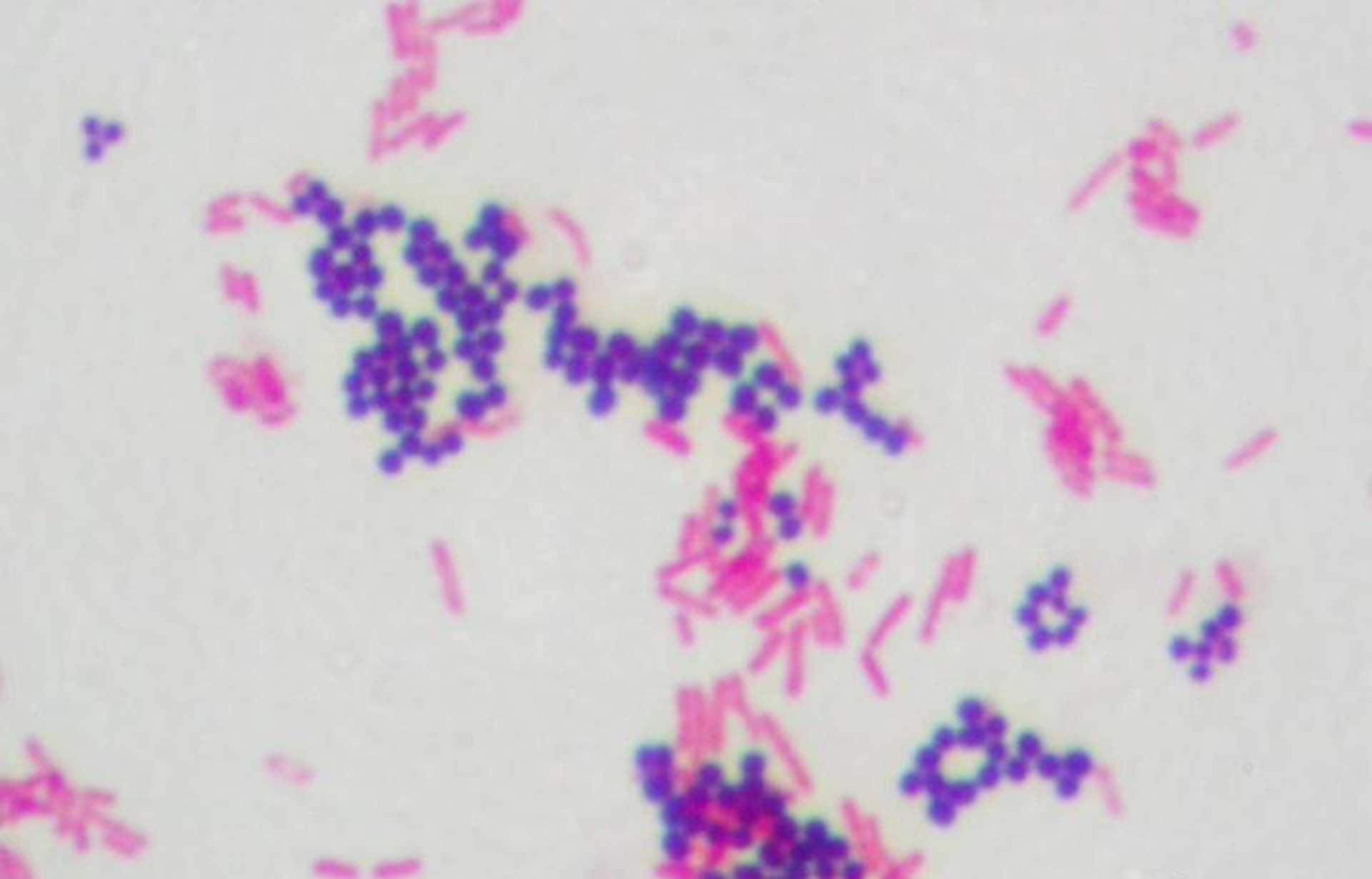




Auramine rhodamine stain:

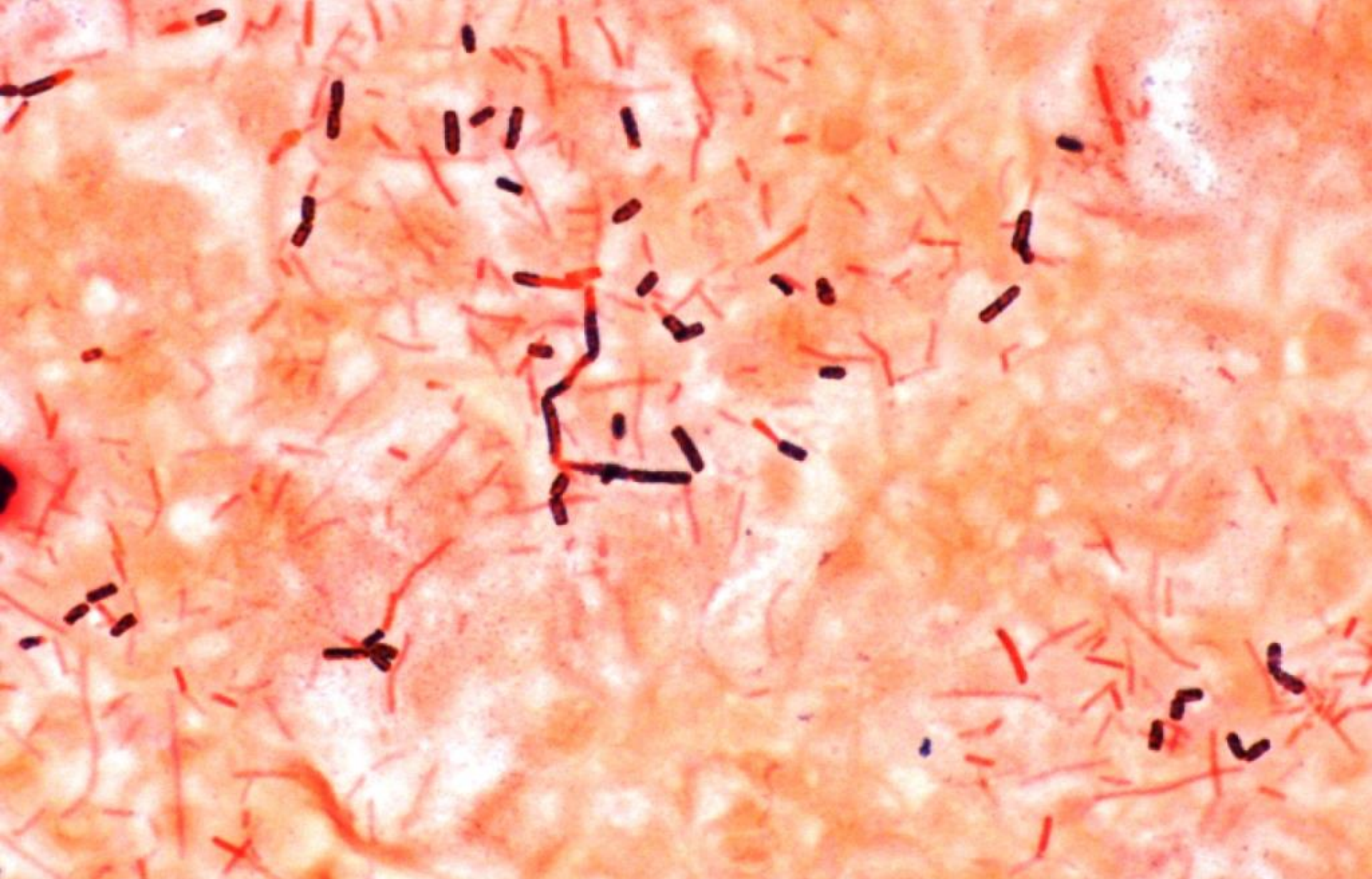
A fluorescence stain, used to highlight acid fast bacilli such as *Mycobacterium*





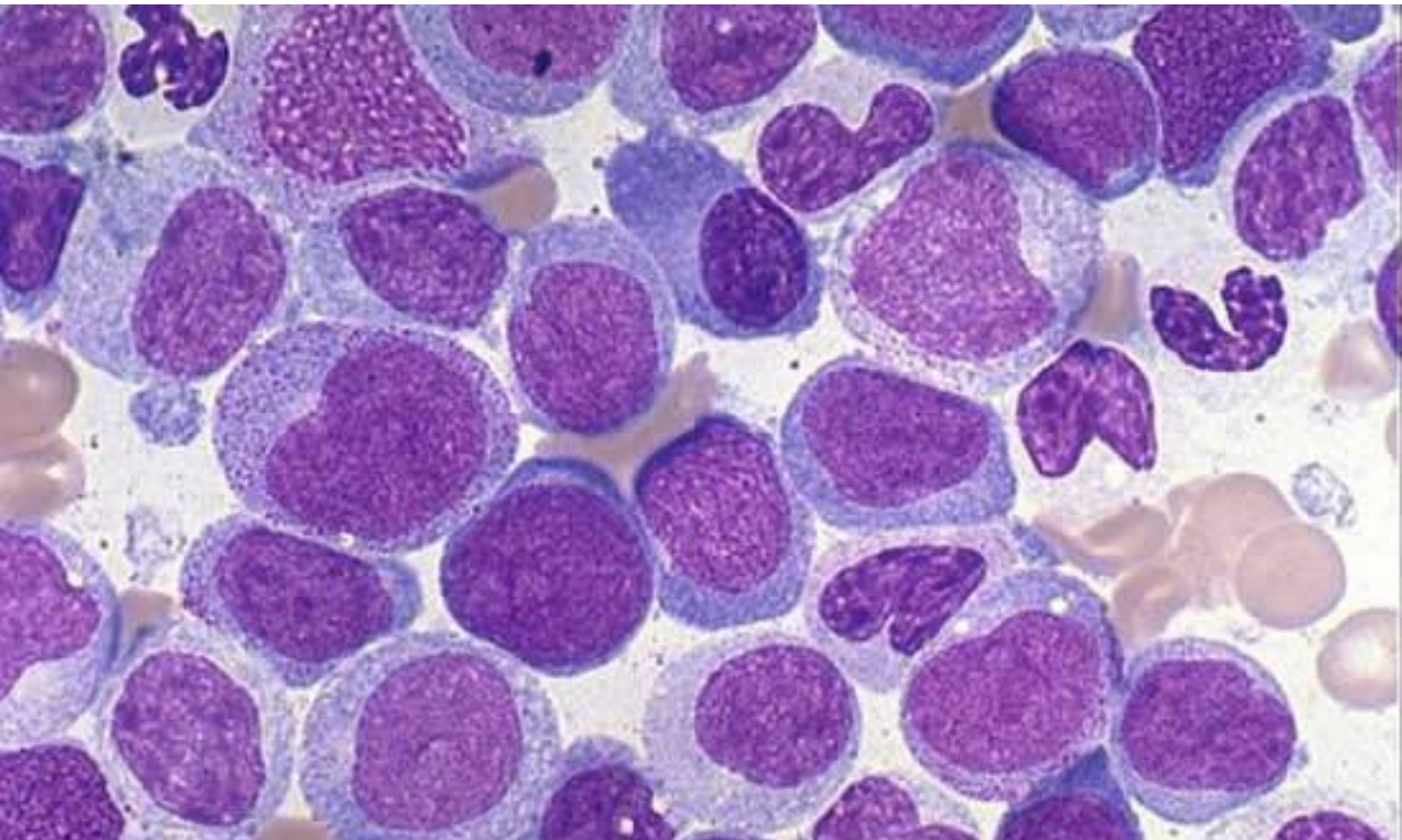
Gram stain:

Differentiates bacteria into gram-positive and gram-negative species



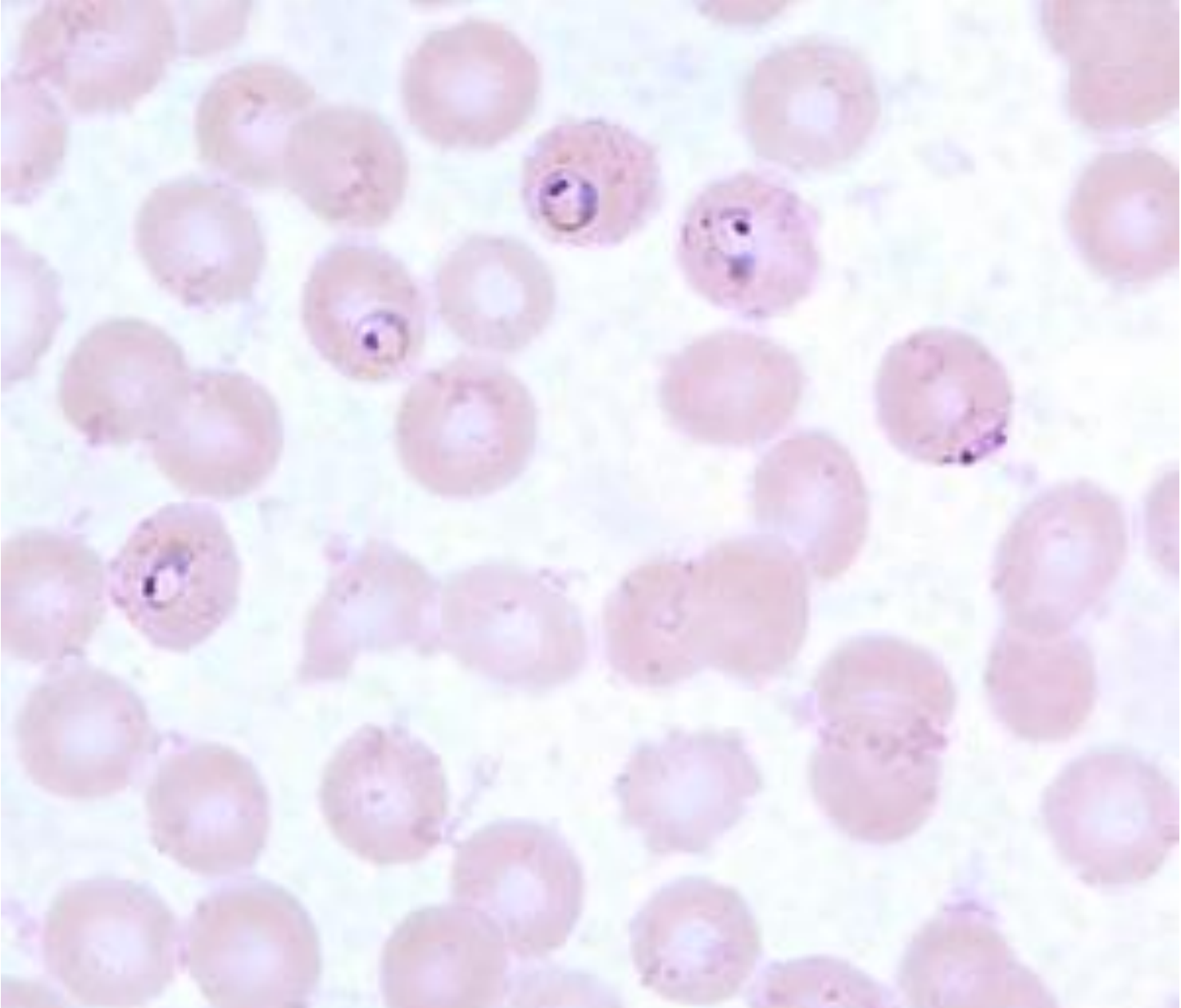
Gram stain:

Differentiates bacteria into gram-positive and gram-negative species



Giemsa stain:

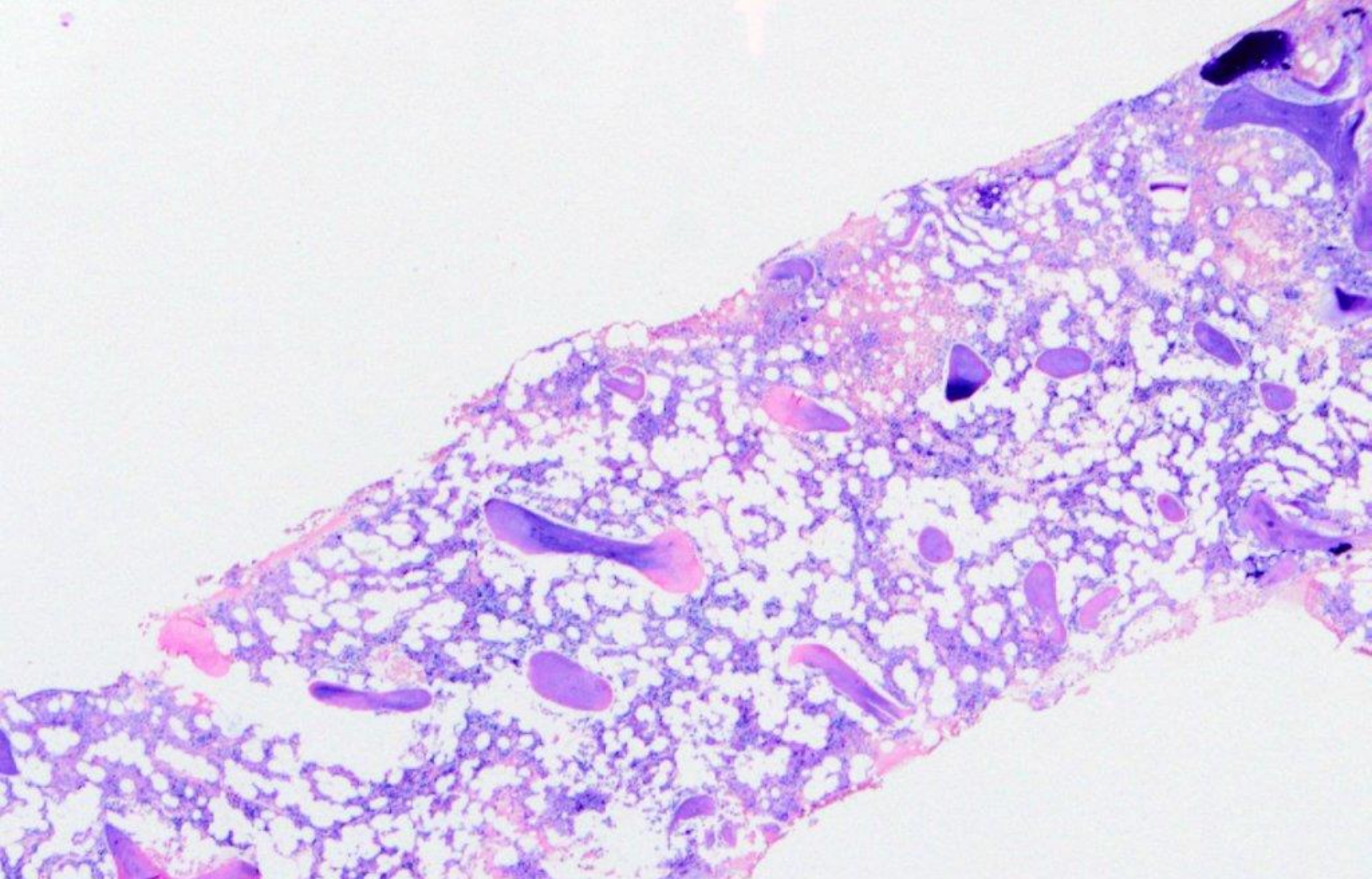
Used in peripheral blood smears



Giemsa stain:

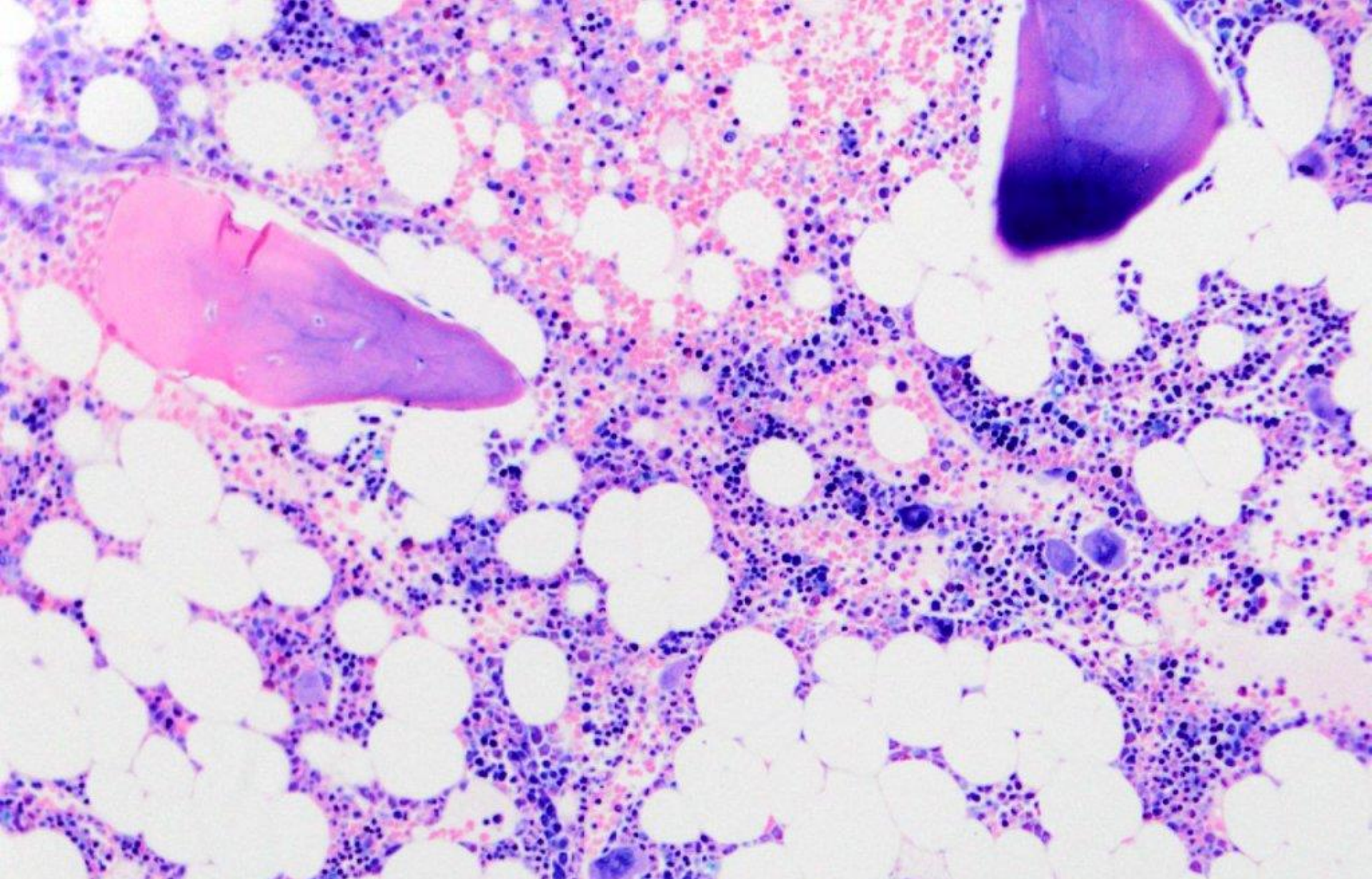
Used in peripheral blood smears





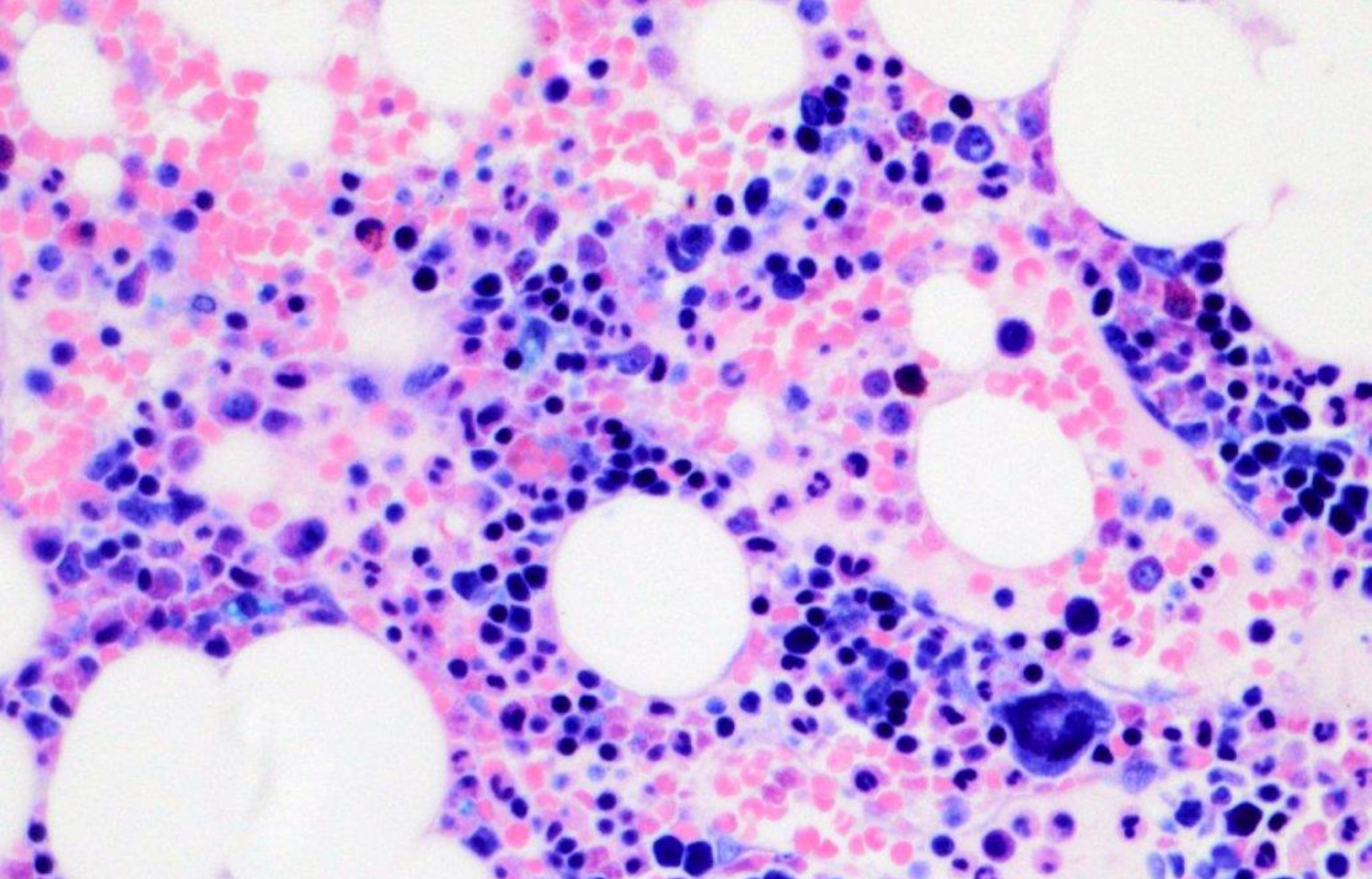
Giemsa stain:

Used in peripheral blood smears



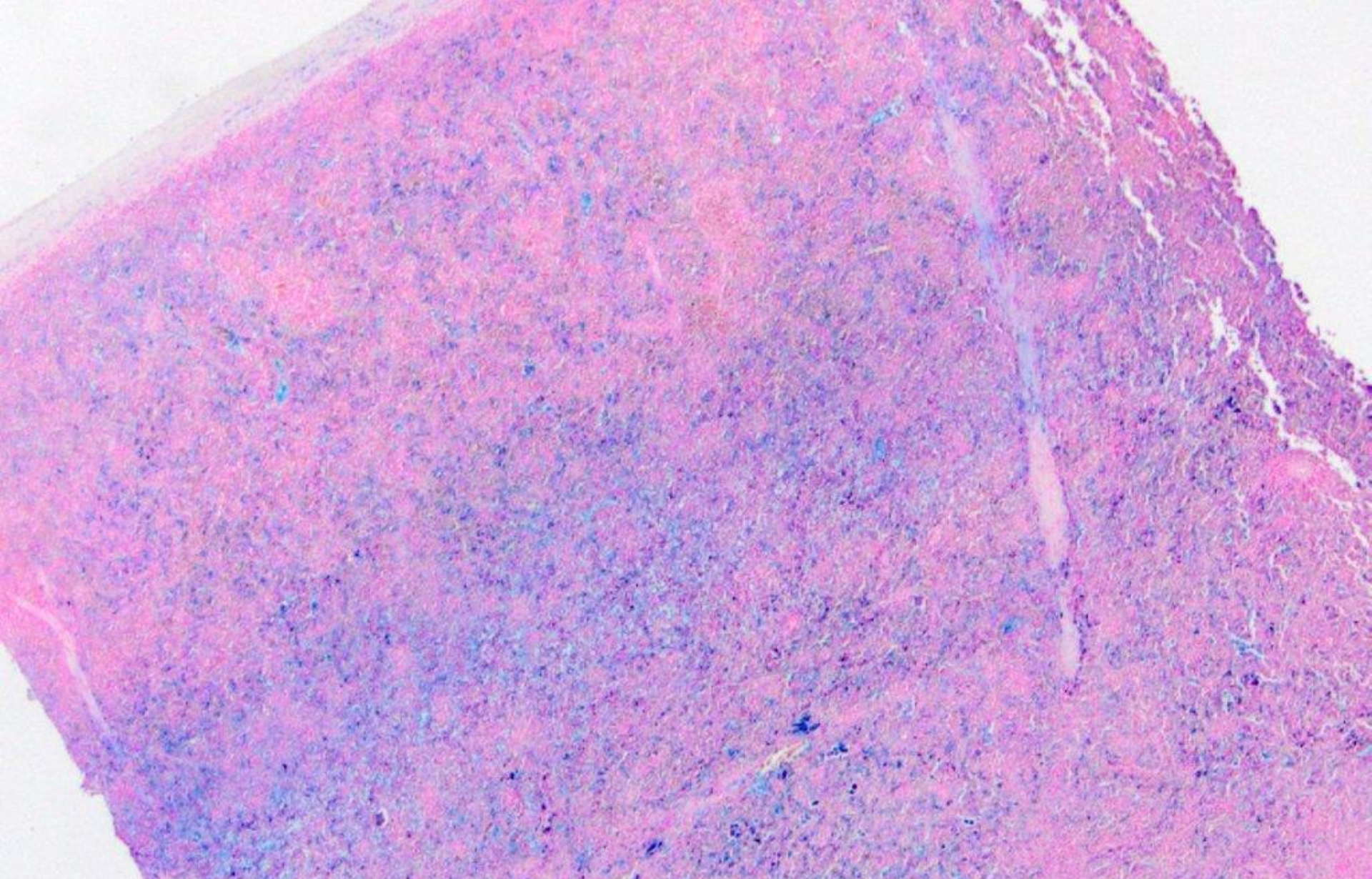
Giemsa stain:

Used in peripheral blood smears



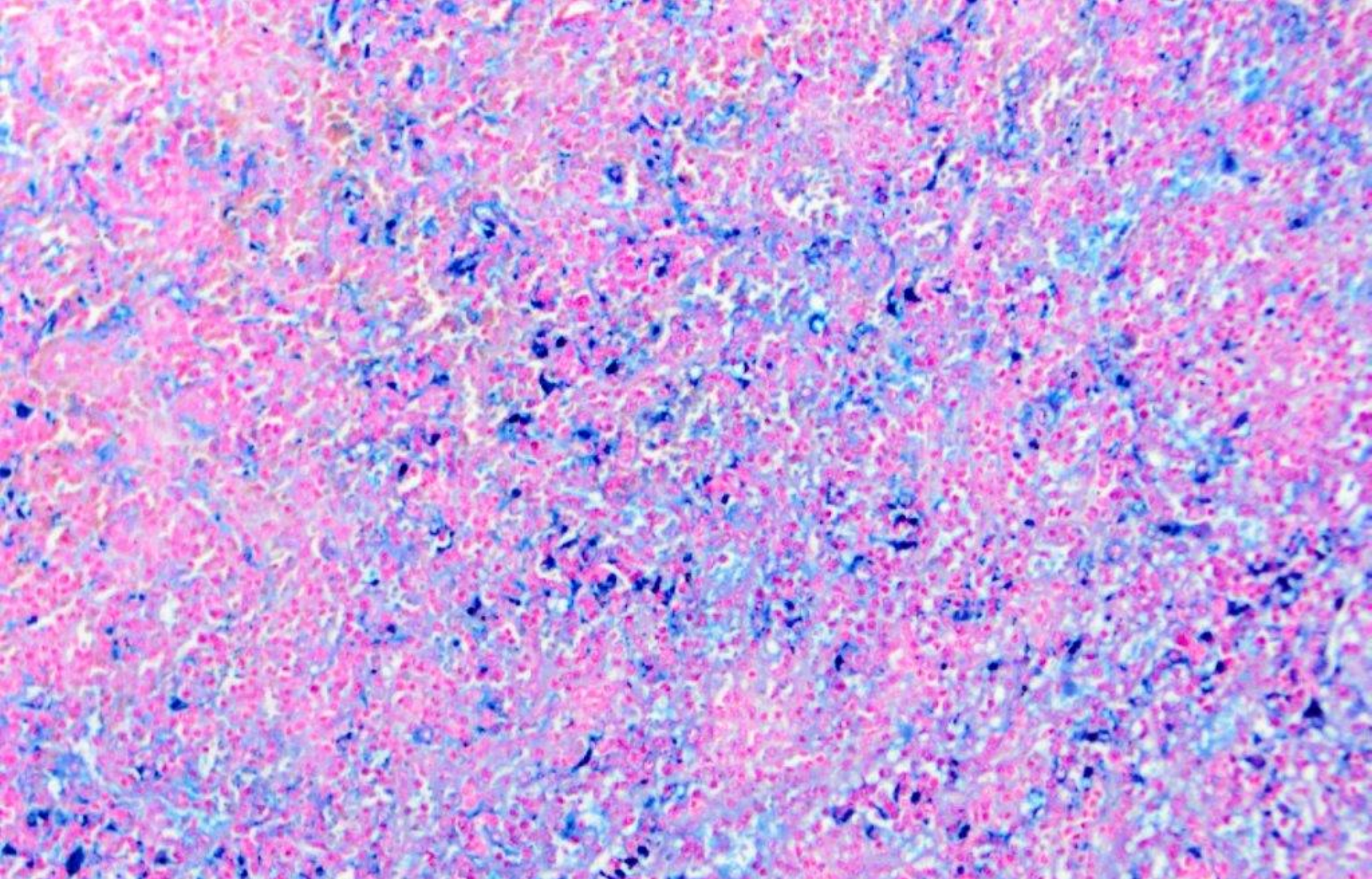
Giemsa stain:

Used in peripheral blood smears



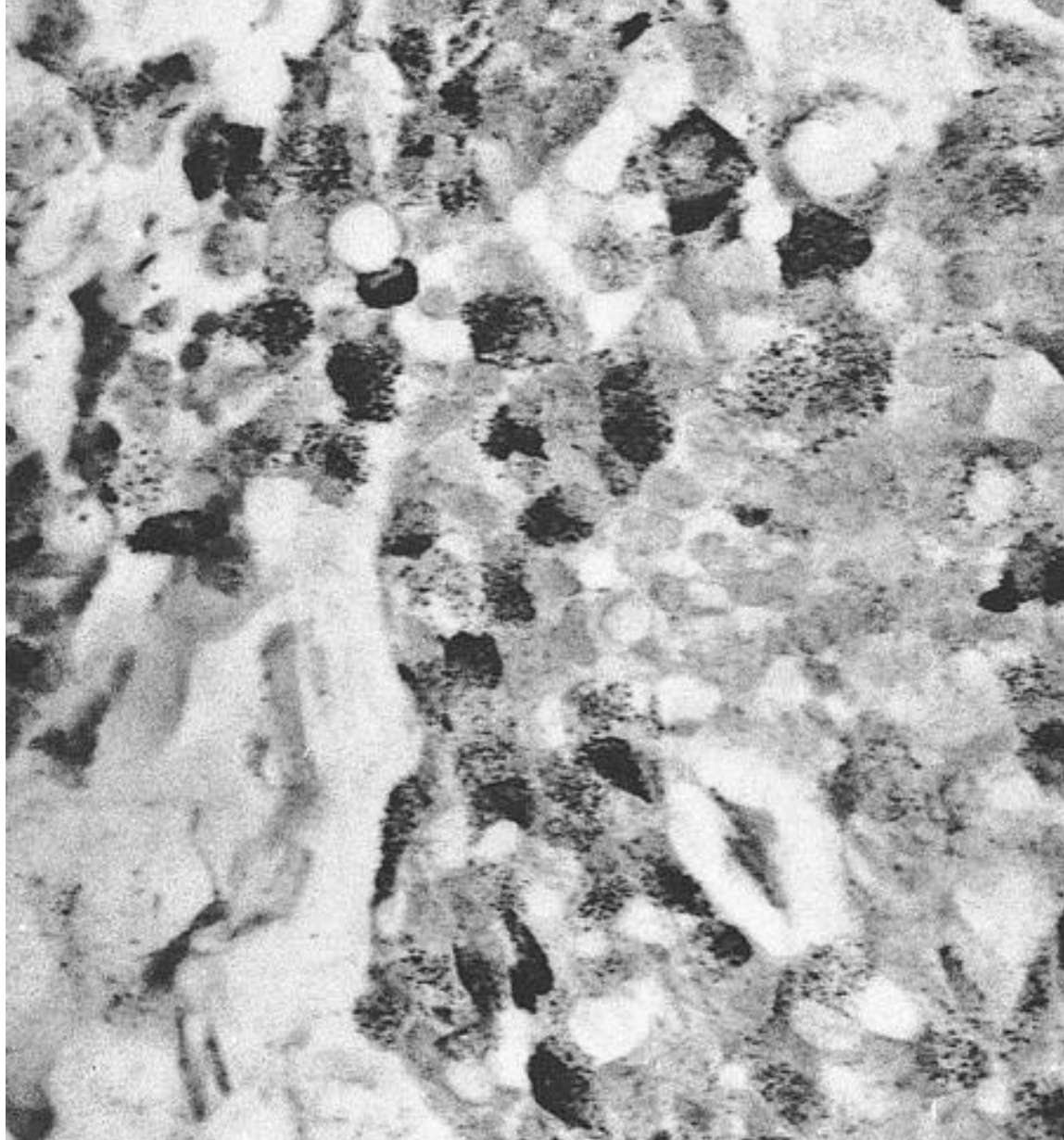
Iron stain (Prussian blue):

Highlights ferric ions in tissues, such as bone marrow samples



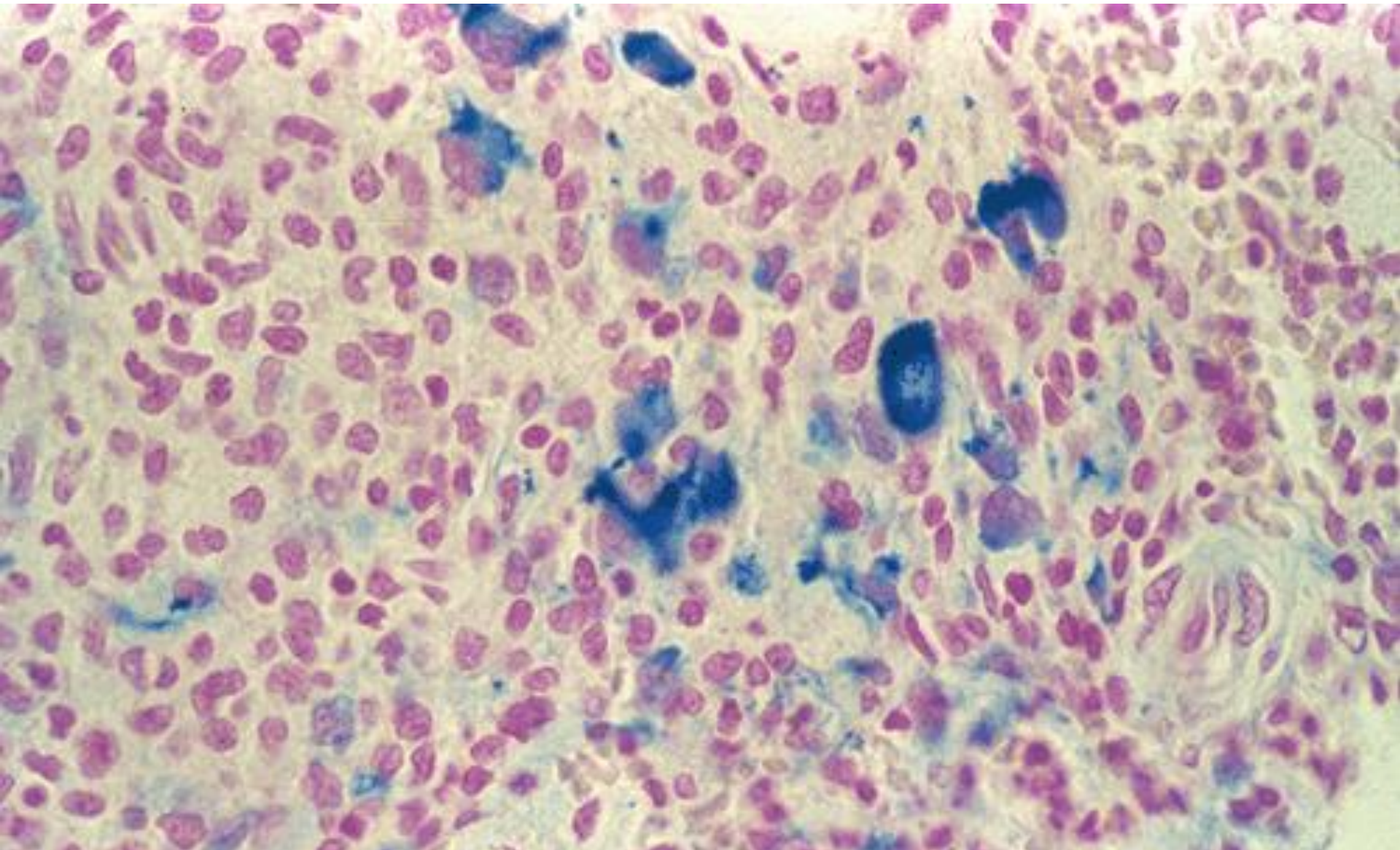
Iron stain (Prussian blue):

Highlights ferric ions in tissues, such as bone marrow samples



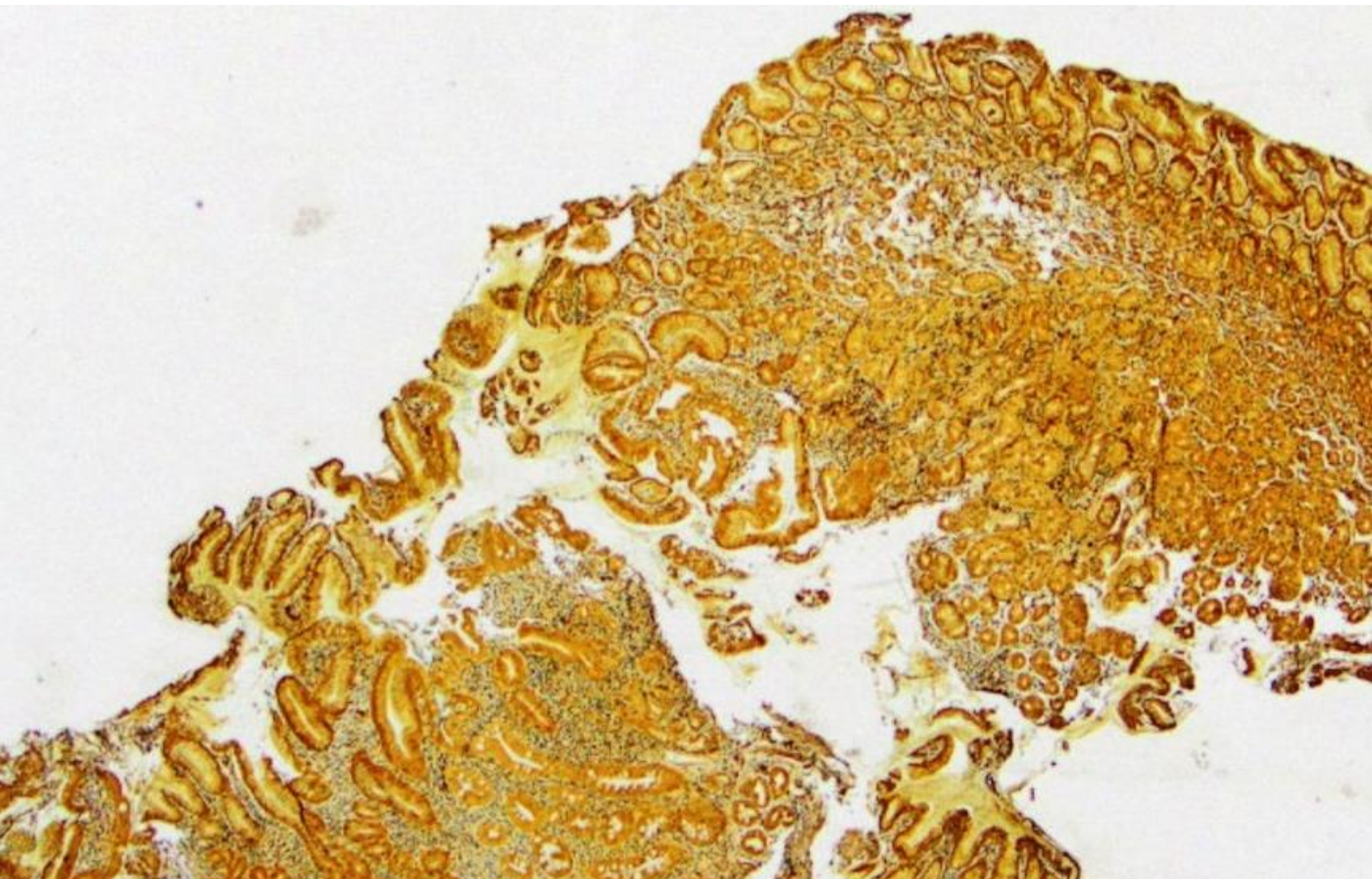
Grimelius (Pascual's modified) stain:

Identifies modified argyrophil cells found in larger numbers in same general locations as argentaffin cells; differentiates carcinoid tumors and neuroendocrine tumors such as Merkel cell carcinoma



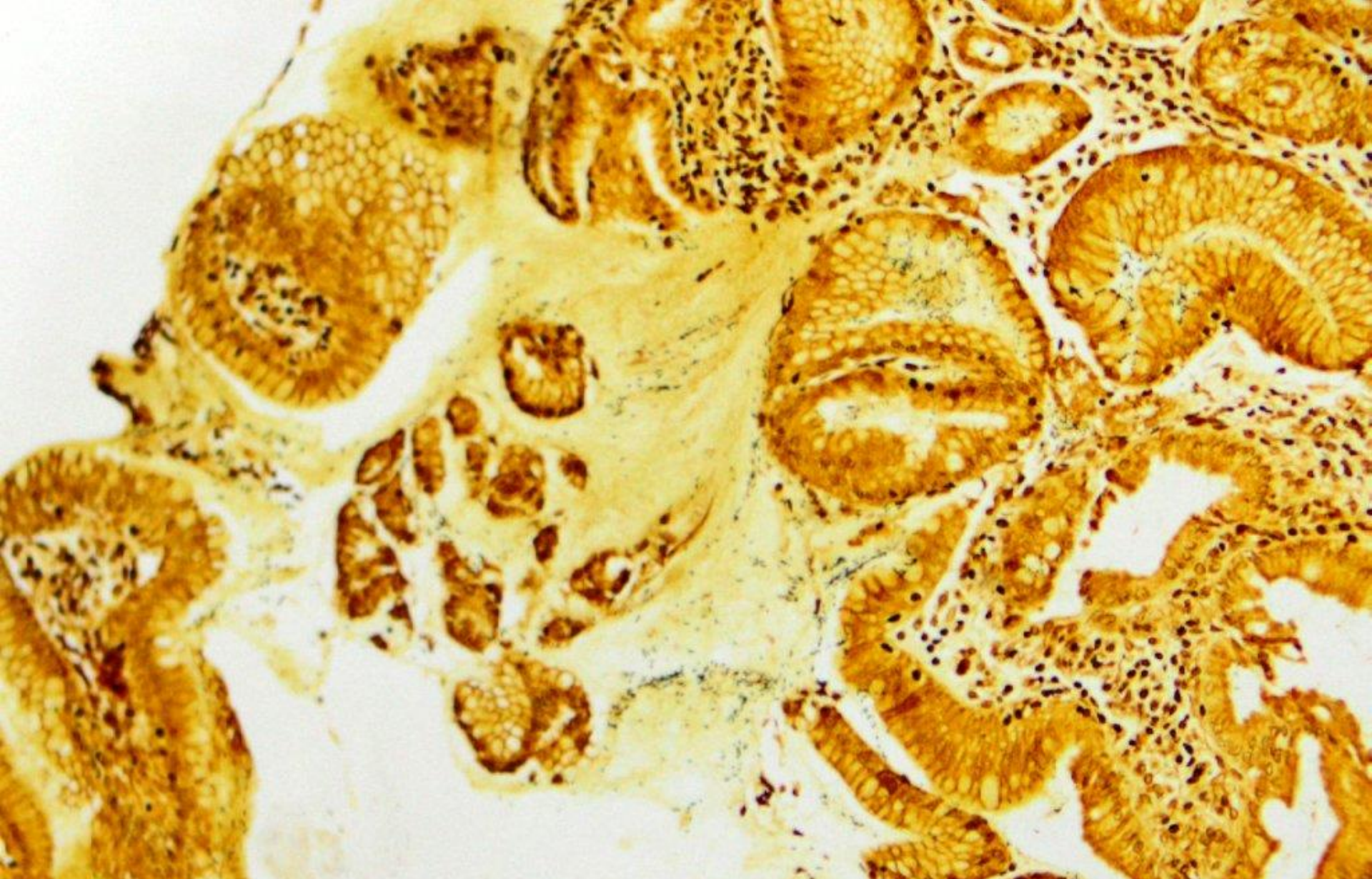
Fontana Masson stain:

Identifies argentaffin cells and melanin pigment



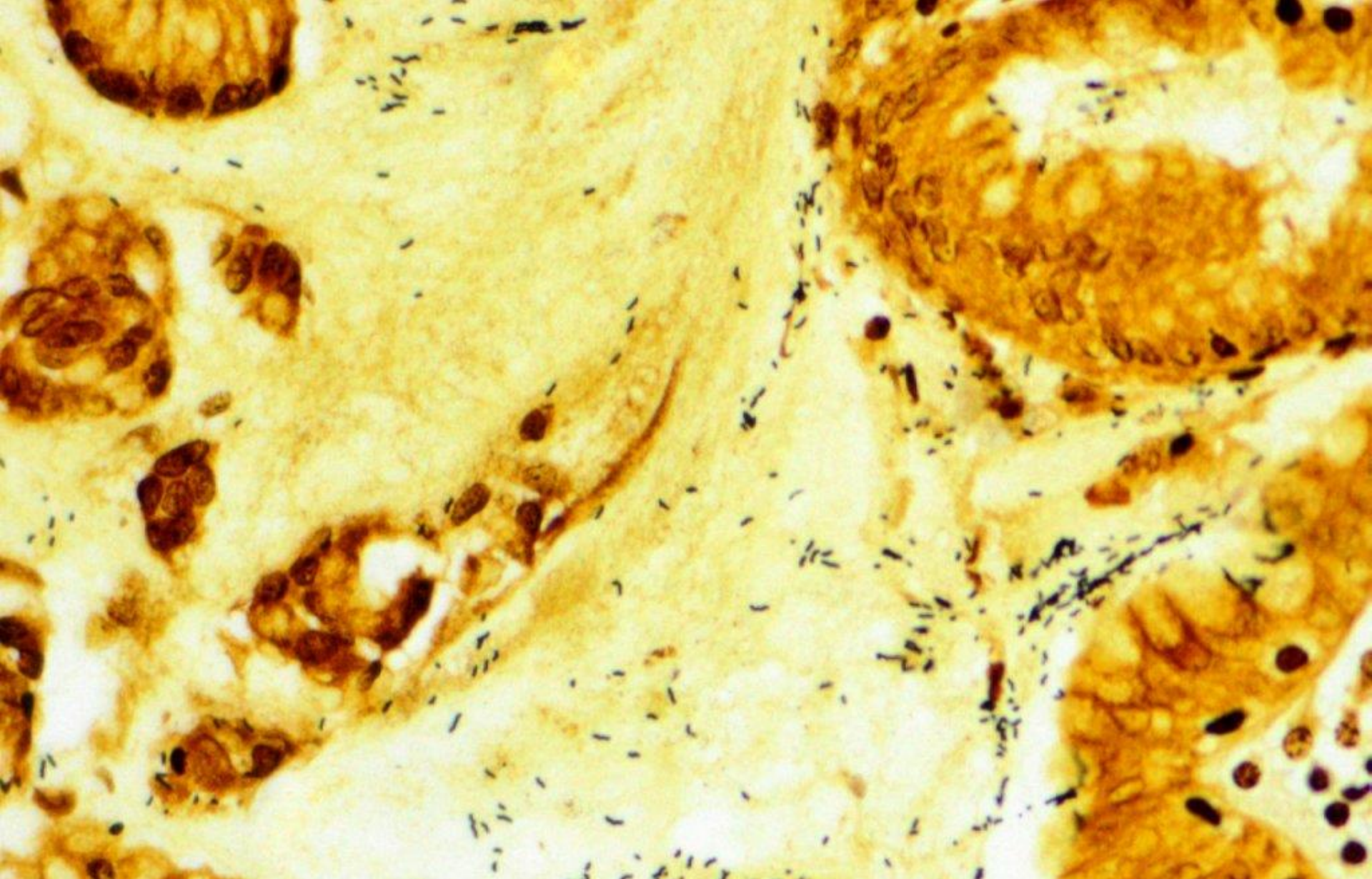
Warthin-Starry stain:

Stains spirochetes



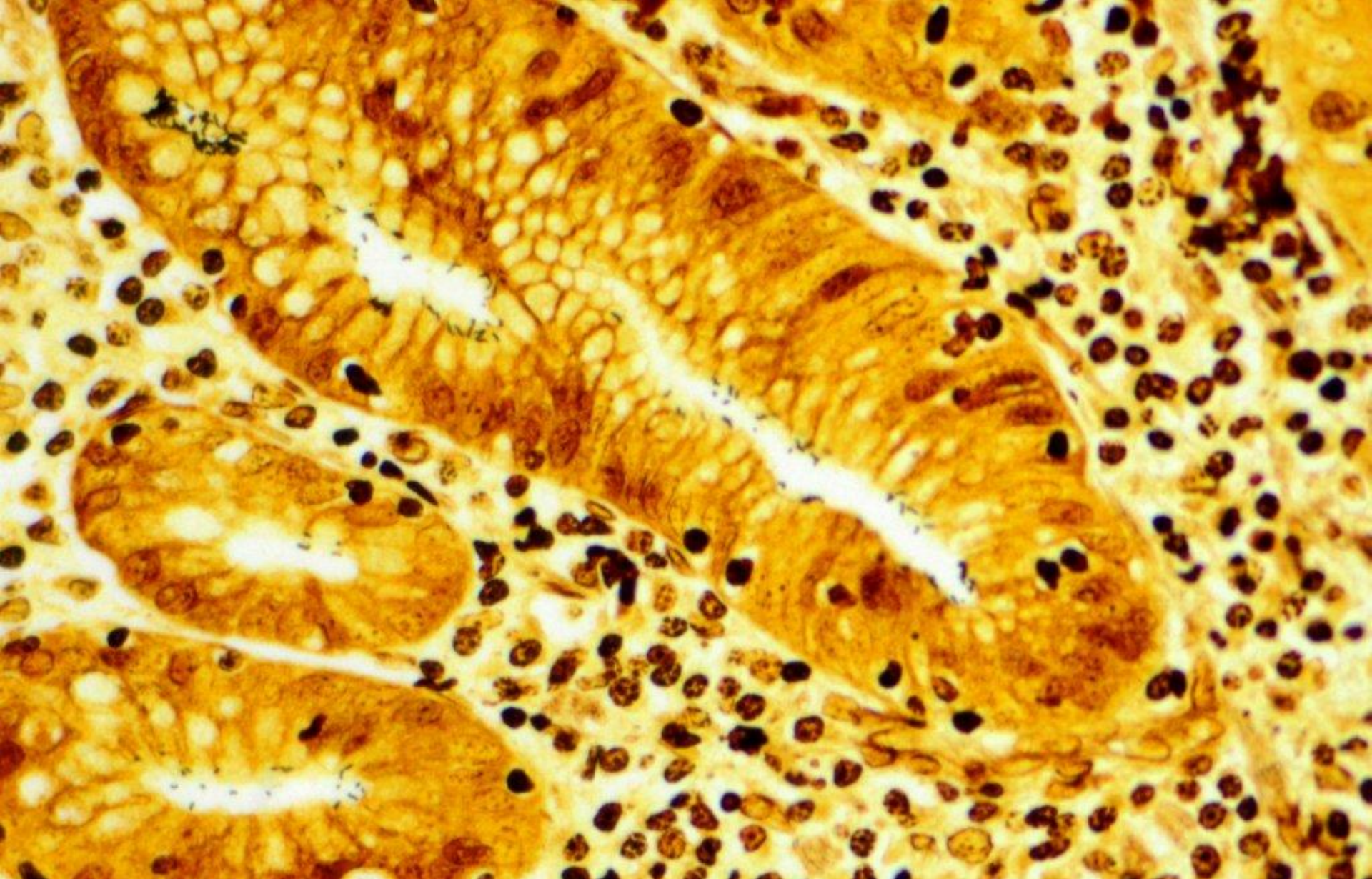
Warthin-Starry stain:

Stains spirochetes



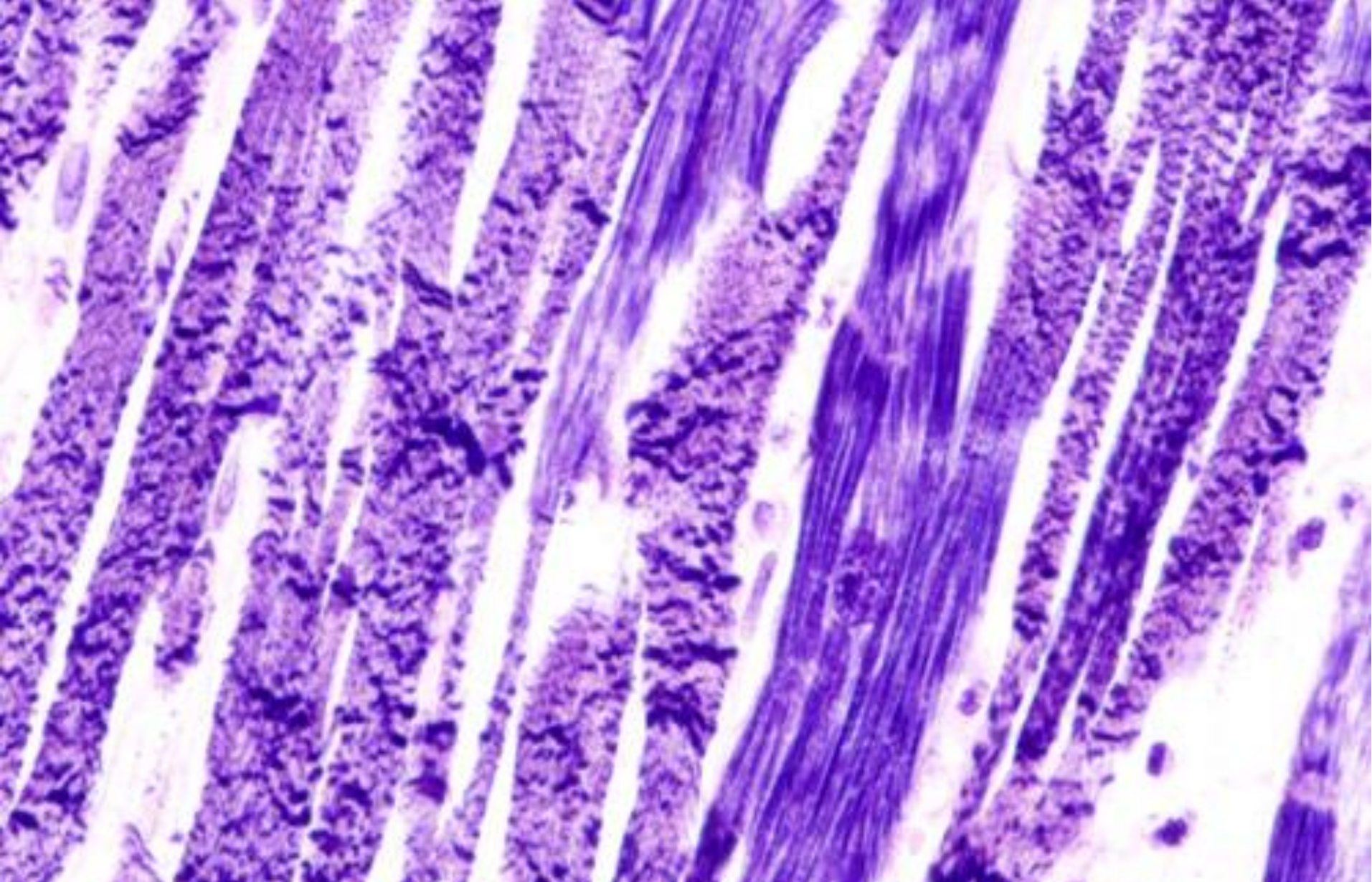
Warthin-Starry stain:

Stains spirochetes



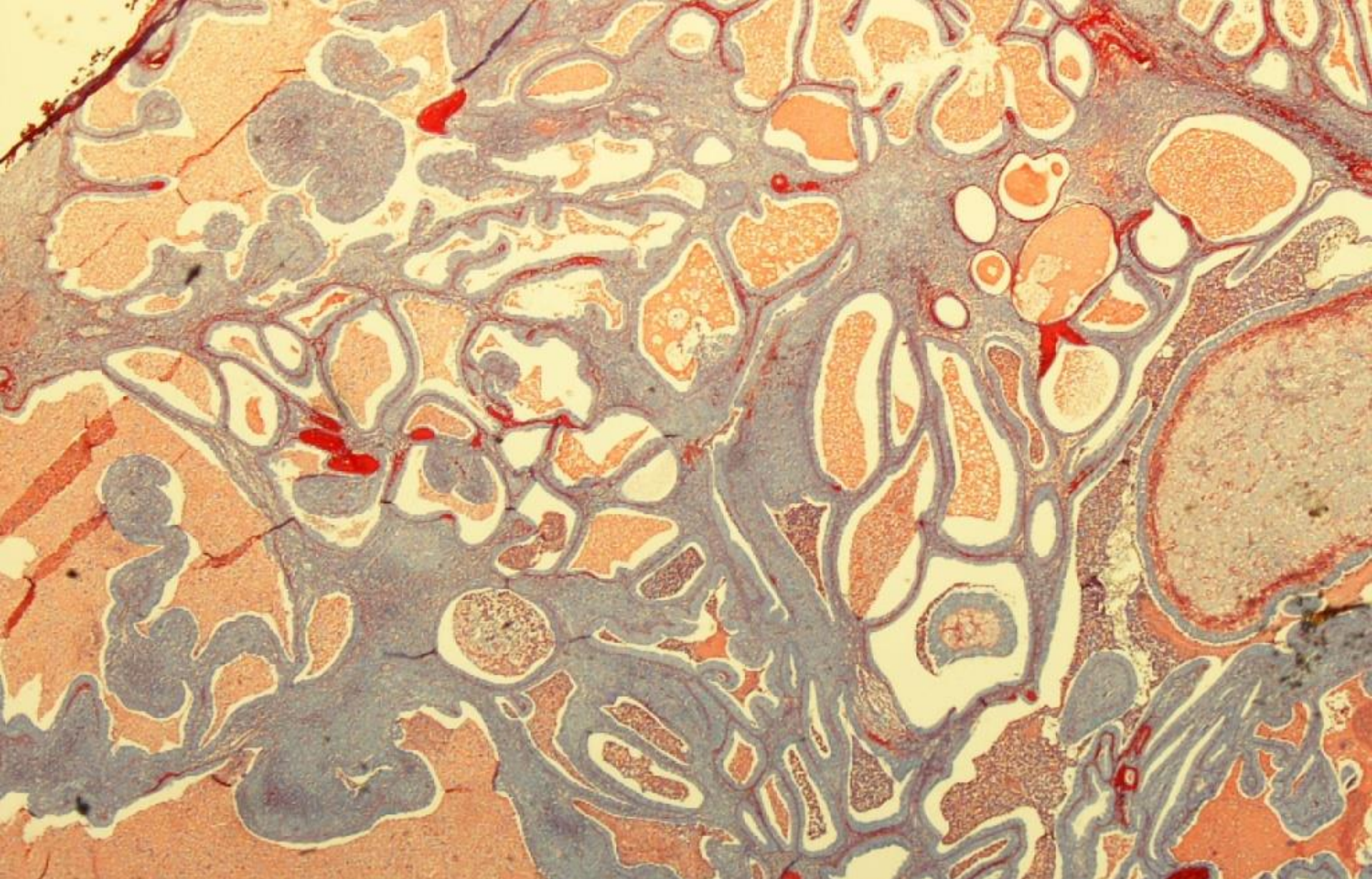
Warthin-Starry stain:

Stains spirochetes



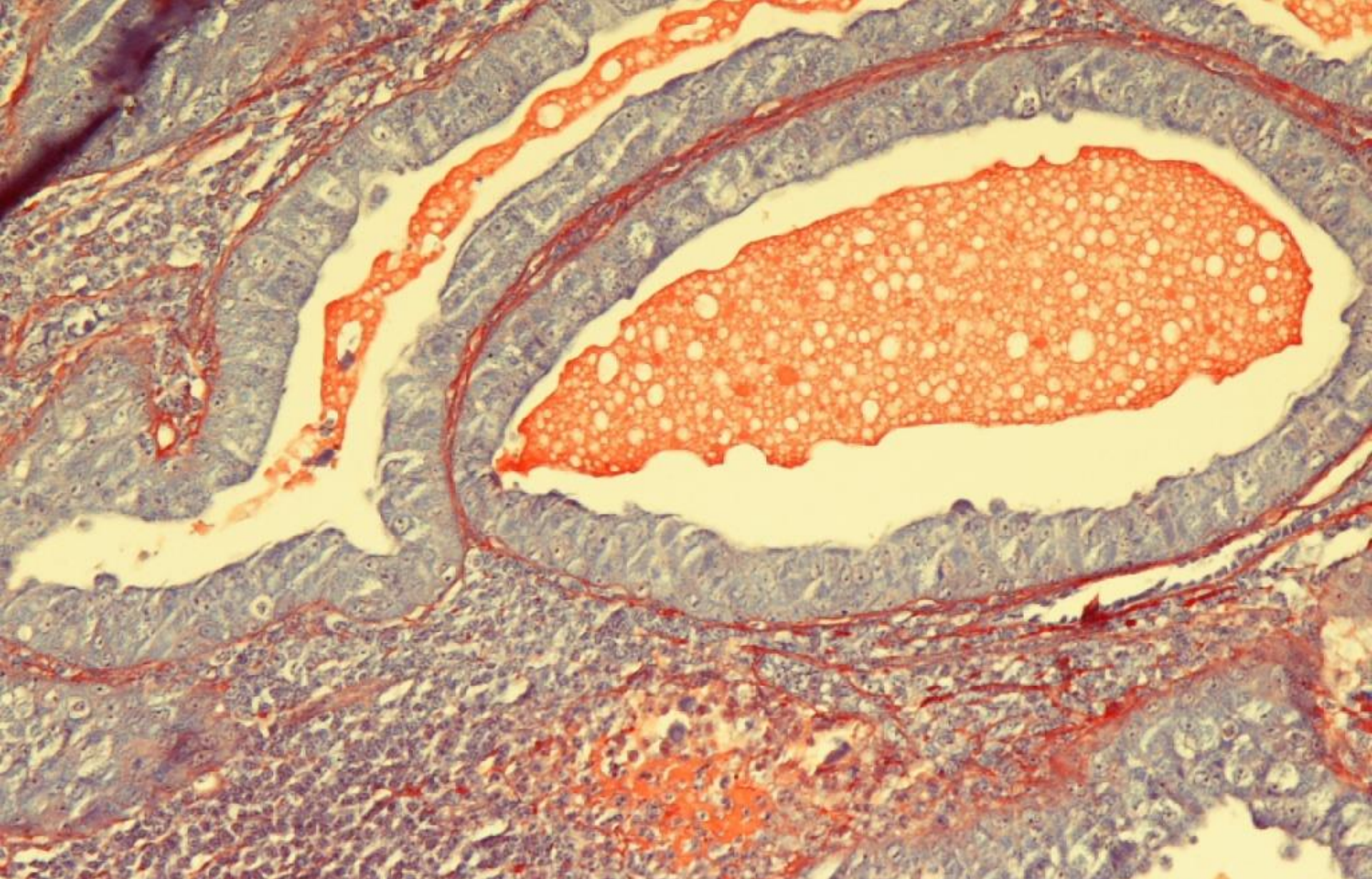
Phosphotungstic acid-haematoxylin (PTAH) / Malloy's stain:

Aids in diagnosing/identifying muscle cross-striations, fibrin, and mitochondria-rich cells



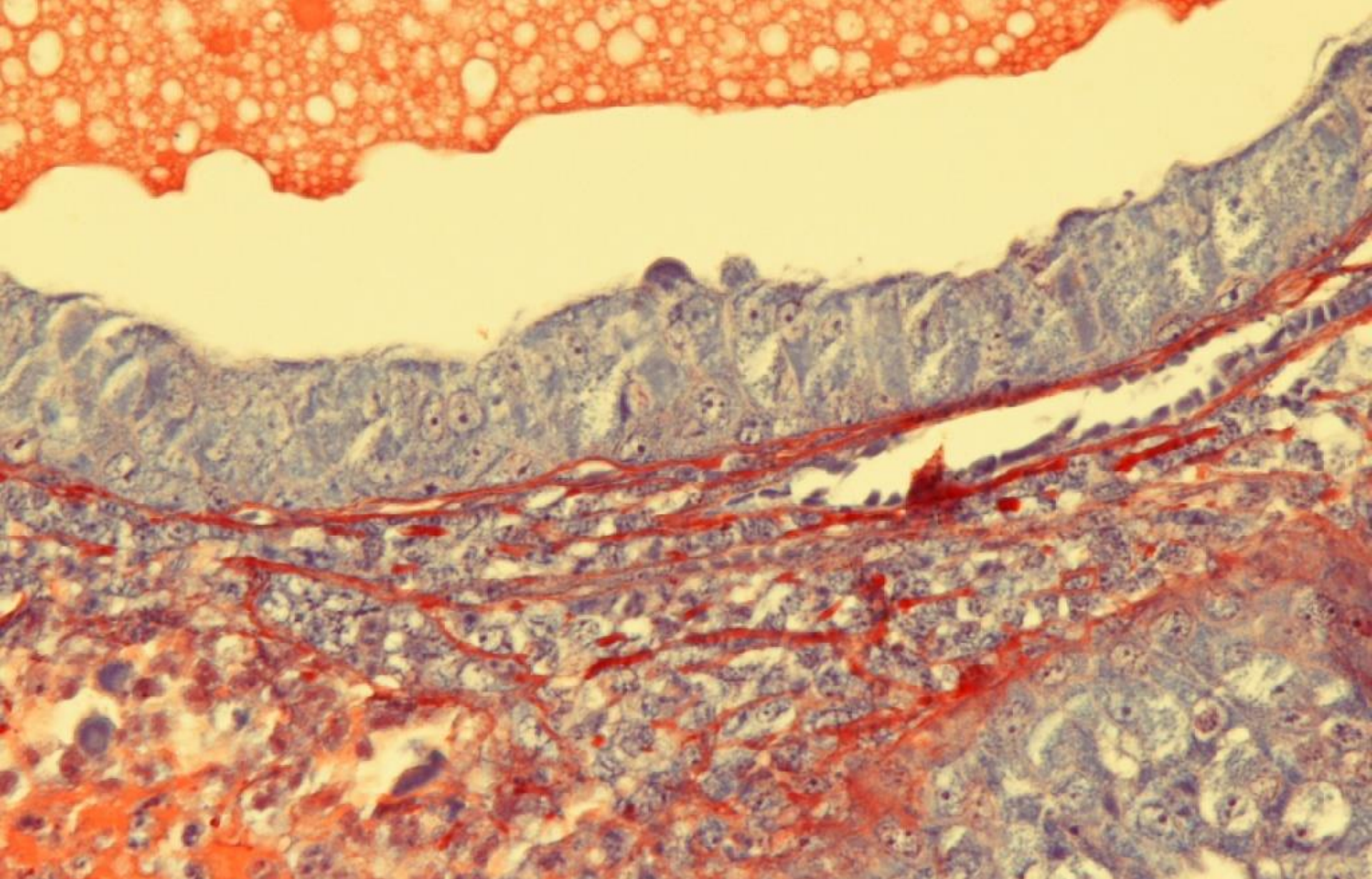
Phosphotungstic acid-haematoxylin (PTAH) / Malloy's stain:

Aids in diagnosing/identifying muscle cross-striations, fibrin, and mitochondria-rich cells



Phosphotungstic acid-haematoxylin (PTAH) / Malloy's stain:

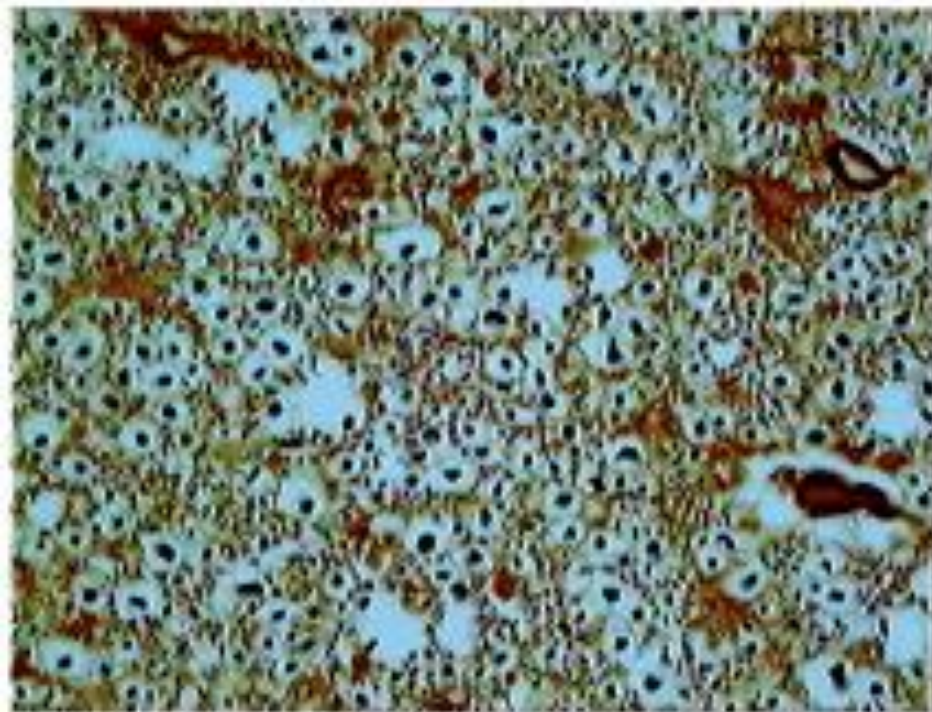
Aids in diagnosing/identifying muscle cross-striations, fibrin, and mitochondria-rich cells



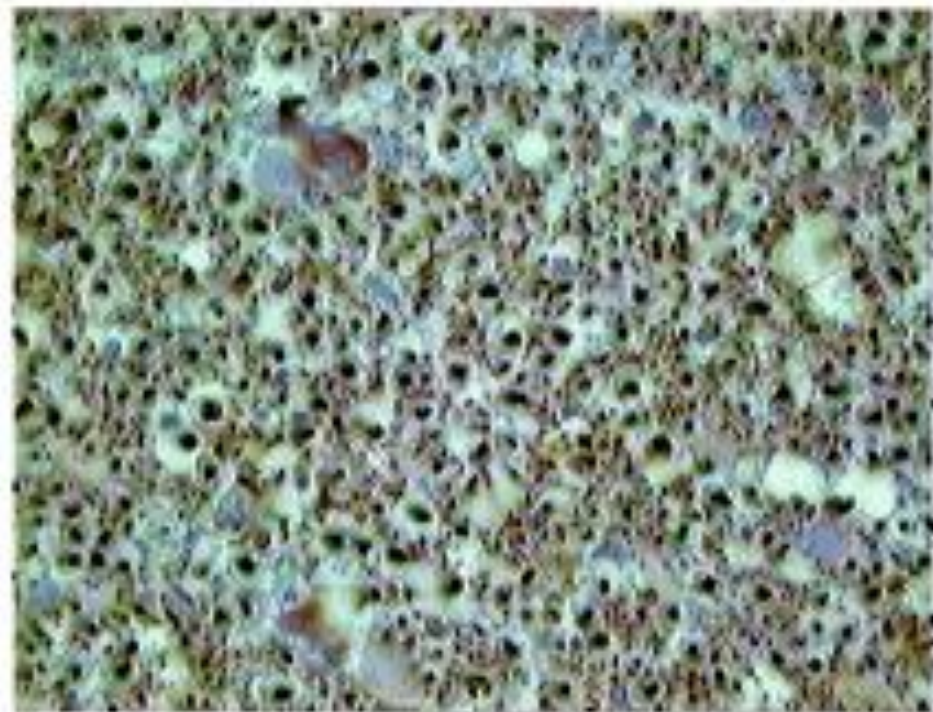
Phosphotungstic acid-haematoxylin (PTAH) / Malloy's stain:

Aids in diagnosing/identifying muscle cross-striations, fibrin, and mitochondria-rich cells

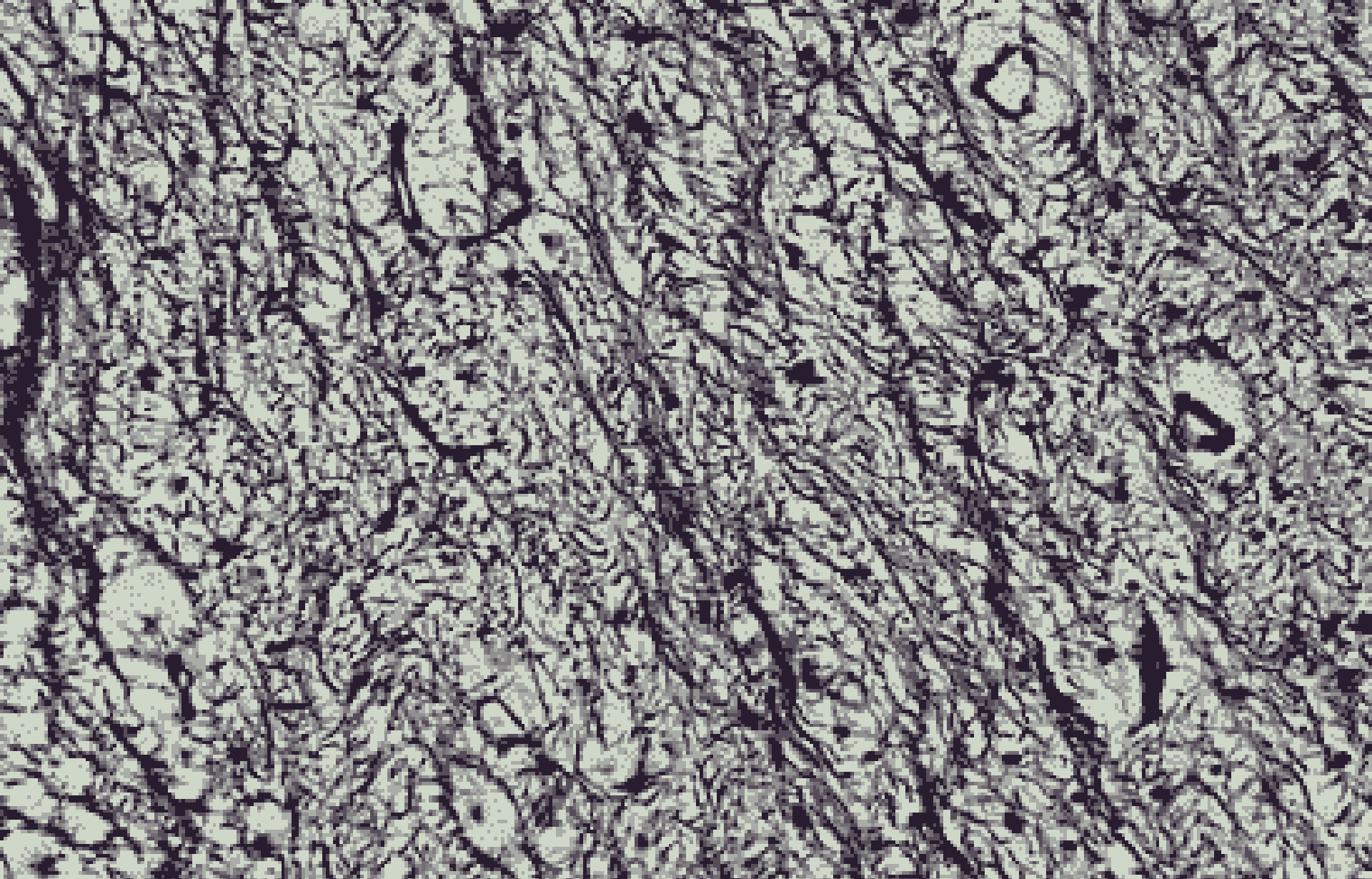
Palmgren



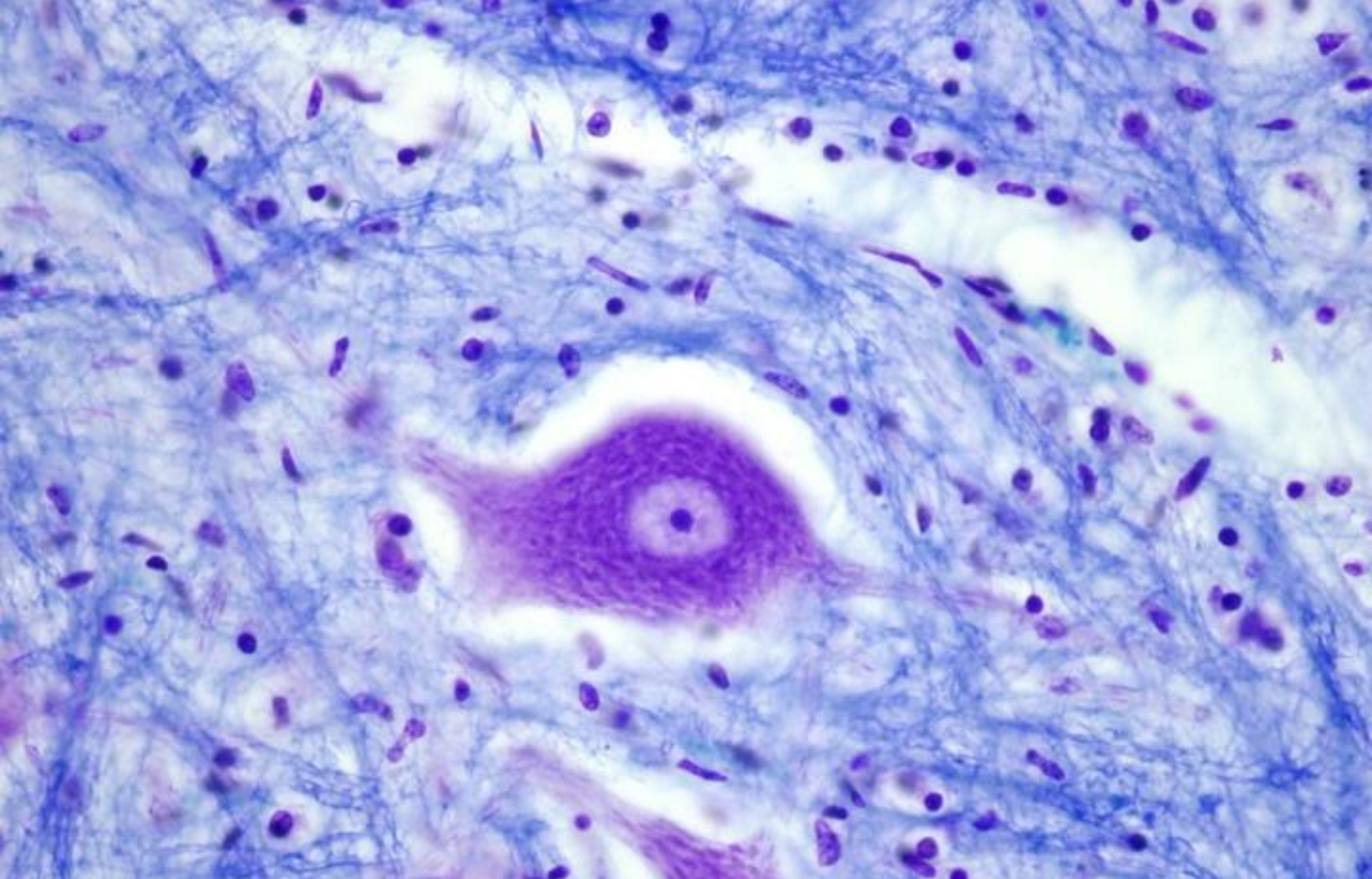
Anti-neurofilament



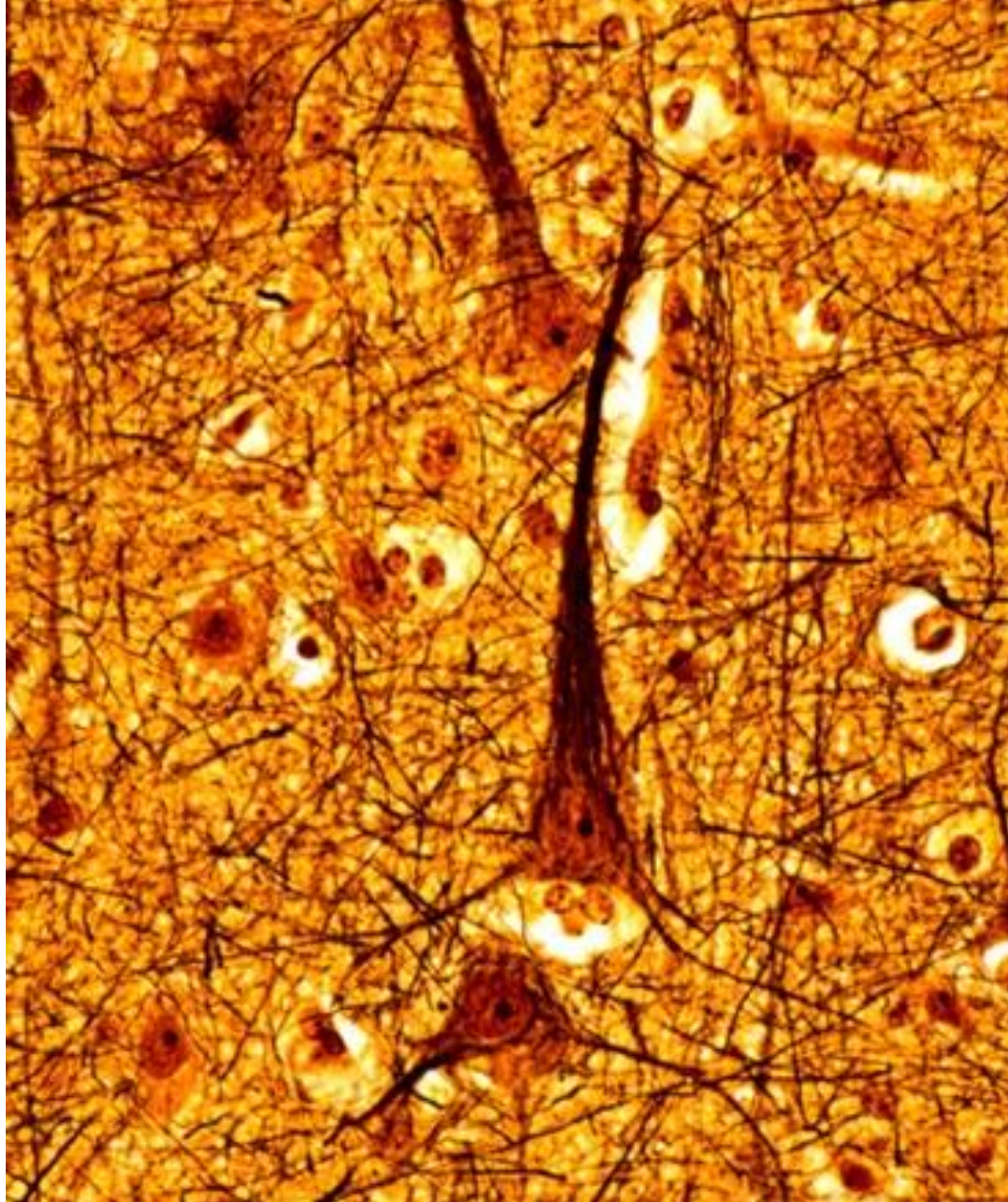
Palmgren stain:
Identifies nerve axons



Bodian stain:
Demonstrates nerve fibers

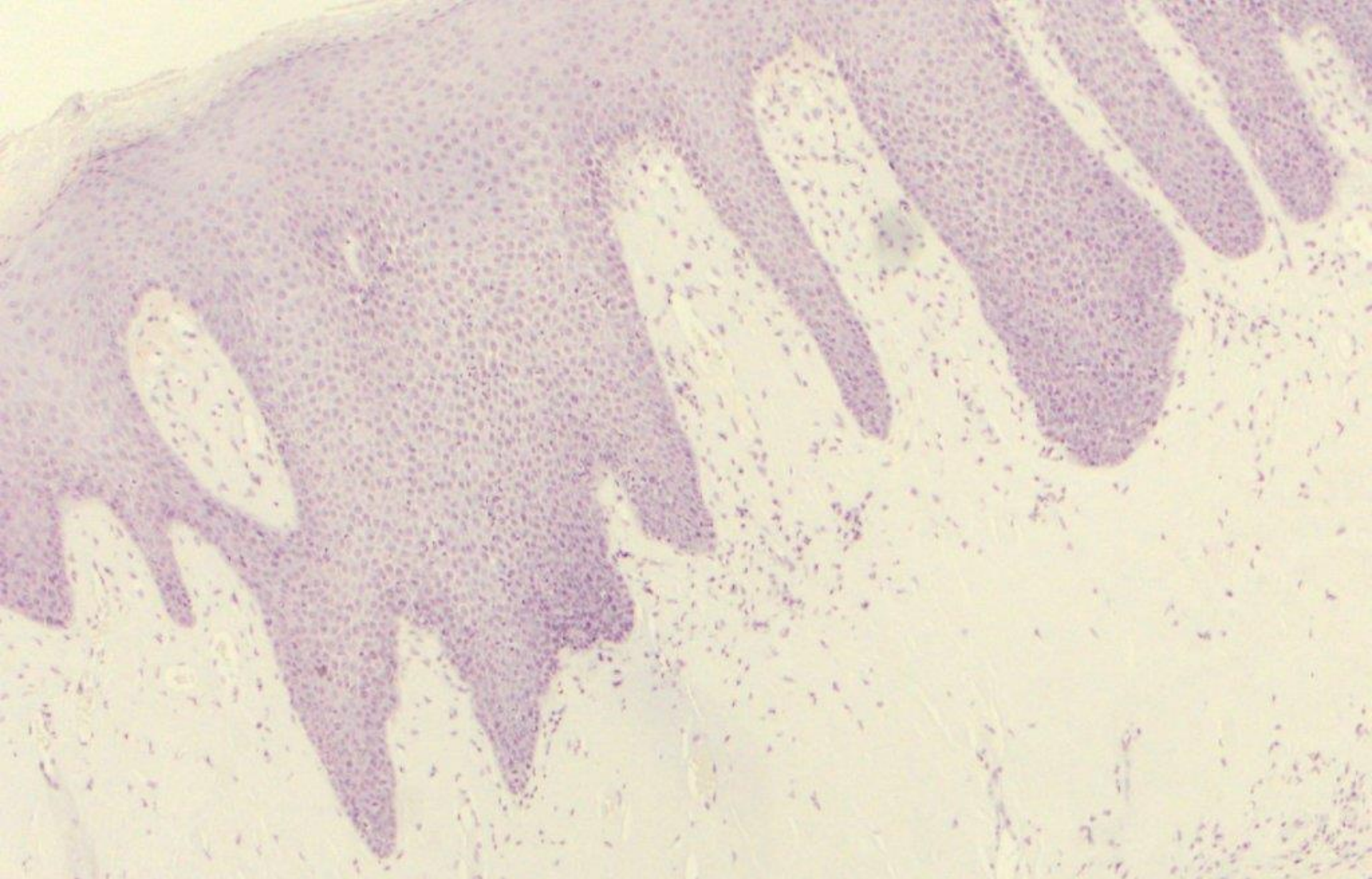


Luxol fast blue/Cresyl violet stain:
Demonstrates myelin sheath



Bielschowsky stain:

Demonstrates neurofibrillary tangles, nerve fibers, and senile plaques; useful in diagnosis of Alzheimer's Disease




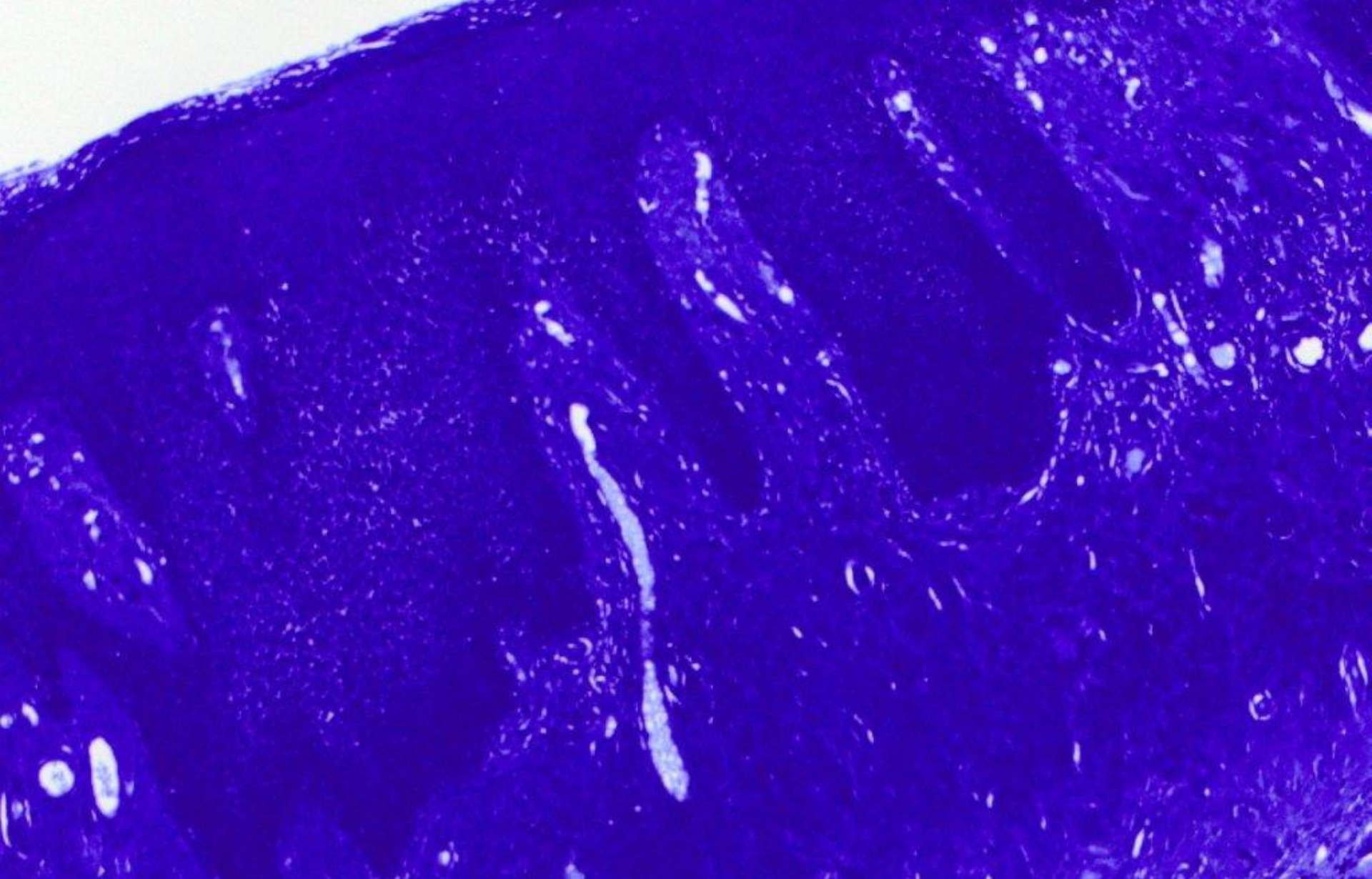
Congo red stain:

Useful as a cytoplasm and erythrocyte stain; amyloid will demonstrate apple green birefringence when viewed under polarized light

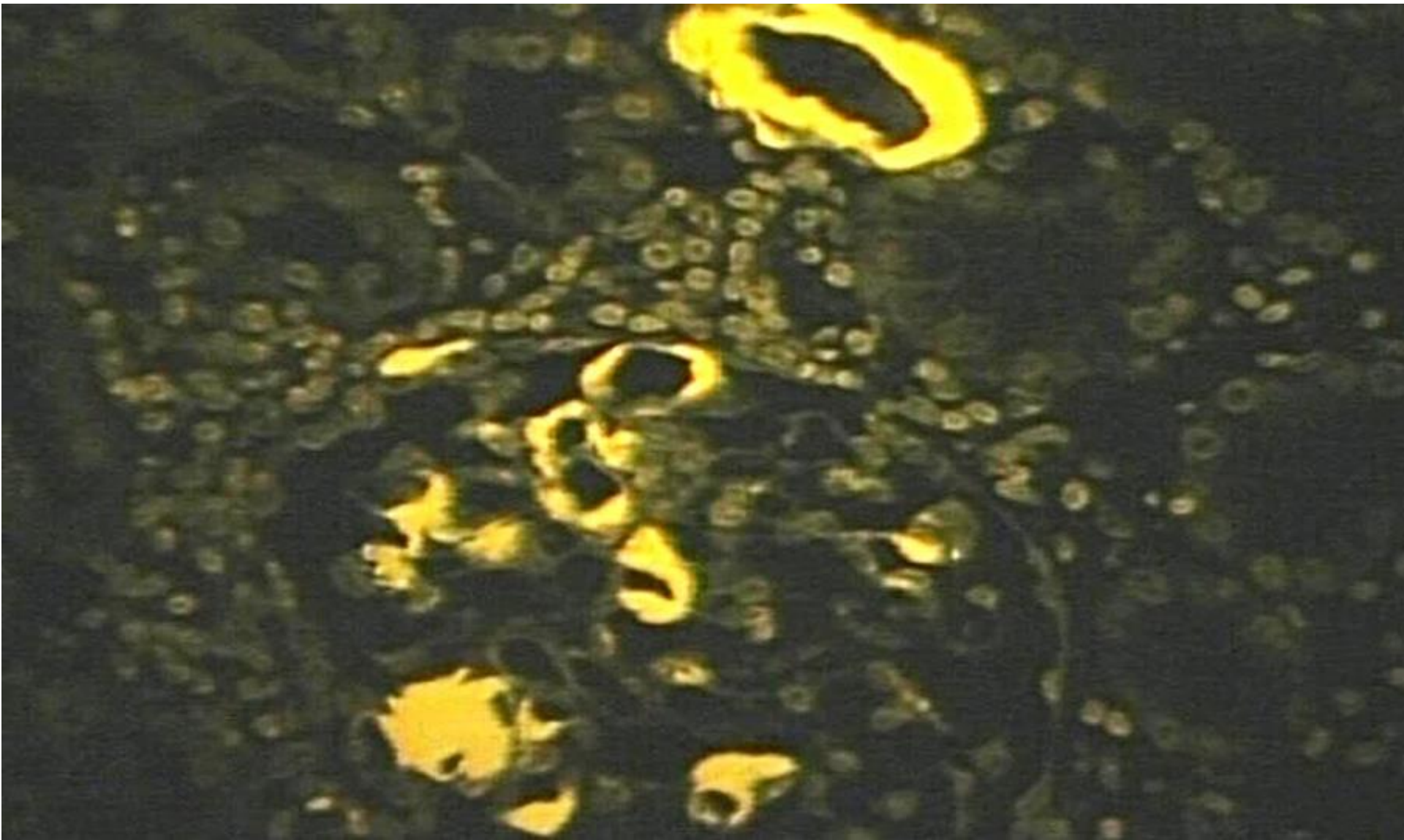
Congo red stain:

Useful as a cytoplasm and erythrocyte stain; amyloid will demonstrate apple green birefringence when viewed under polarized light





Crystal violet stain:
Demonstrates amyloid



Thioflavin T stain:

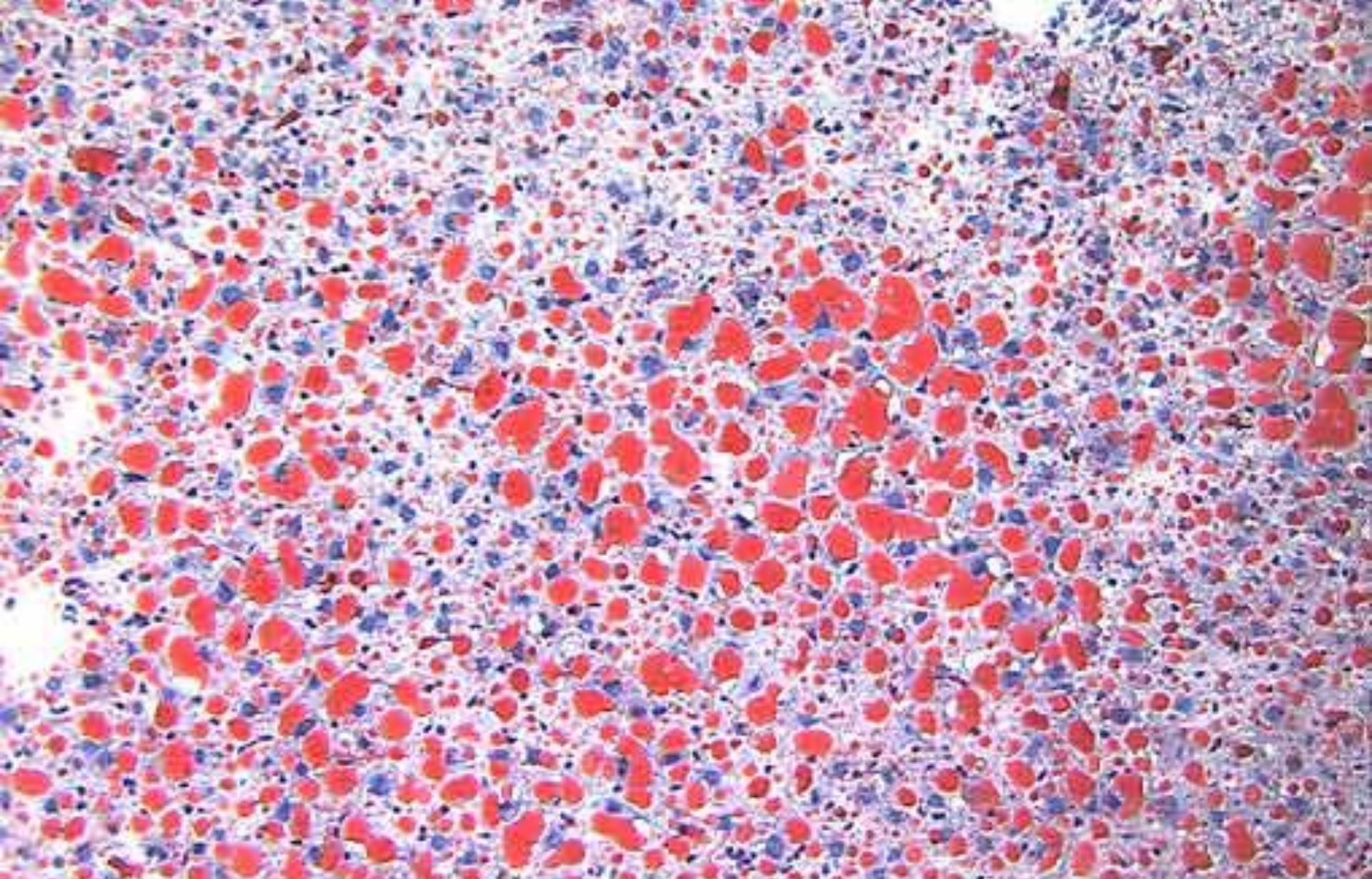
Fluorescent stain which demonstrates amyloid; useful in Alzheimer's diagnosis



B

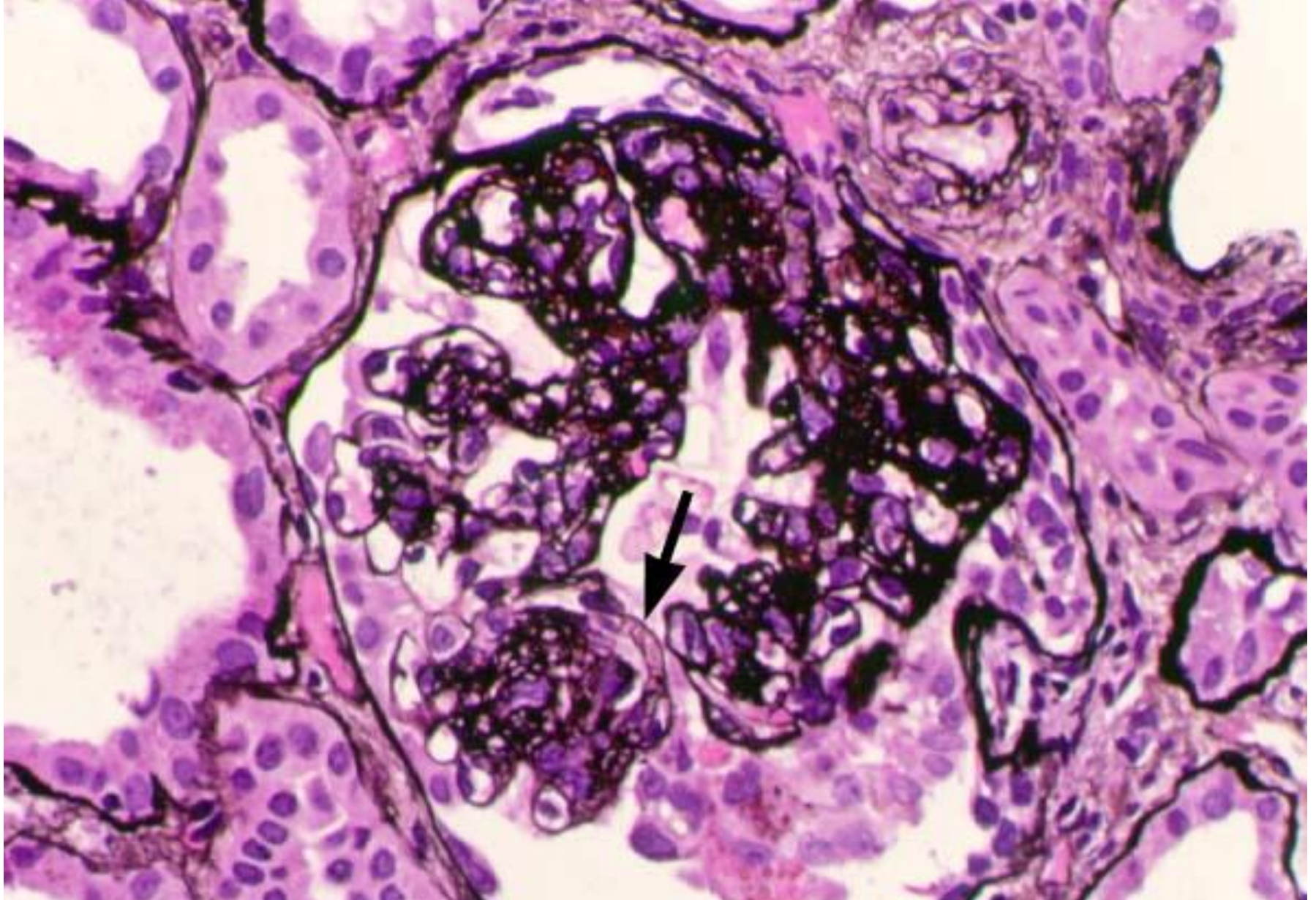
Sudan IV stain:

Stains lipids, triglycerides, and lipoproteins



Oil Red O stain:

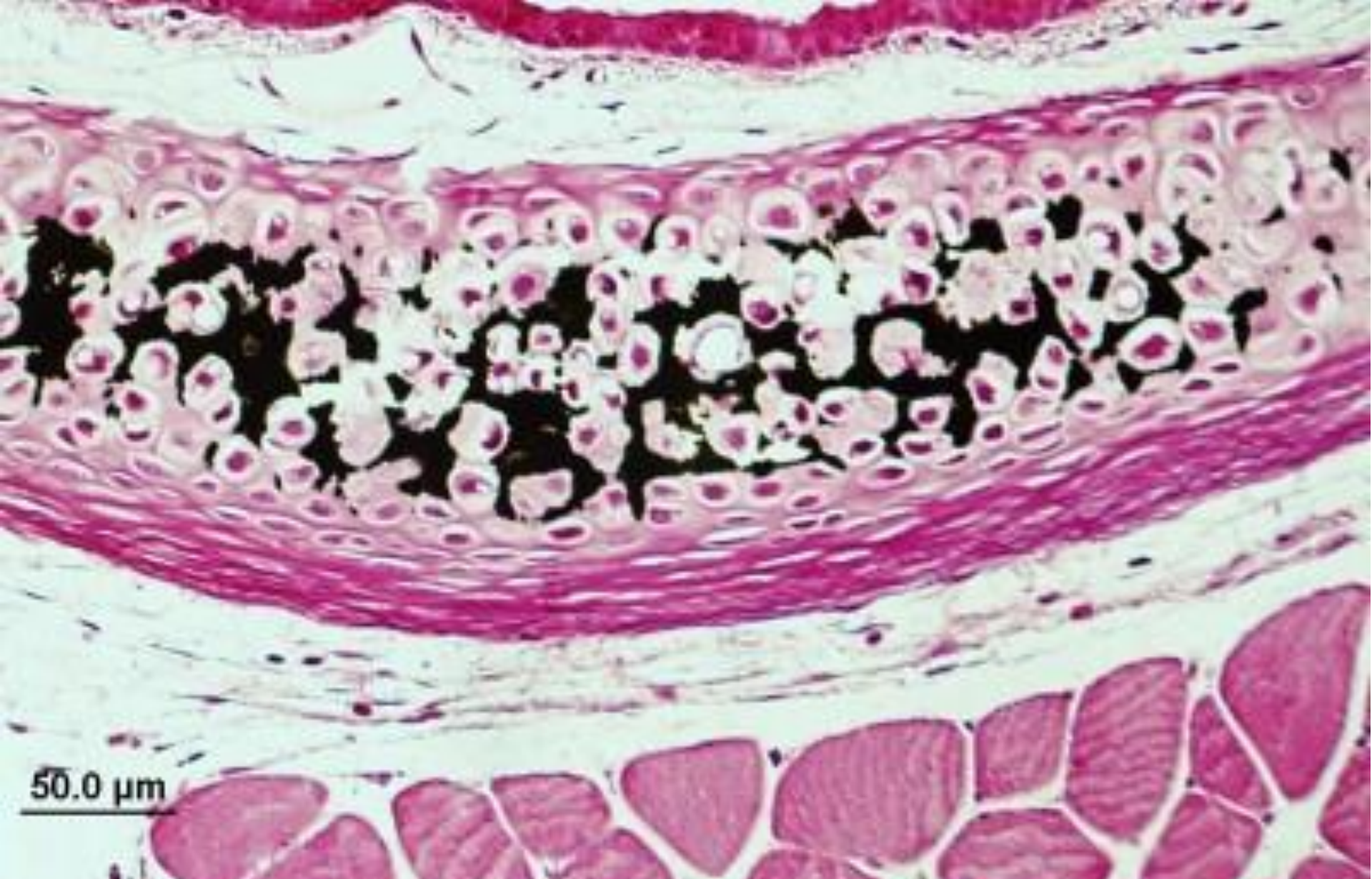
Demonstrates fat/lipids in fresh (frozen) tissue



Jones methenamine silver stain:

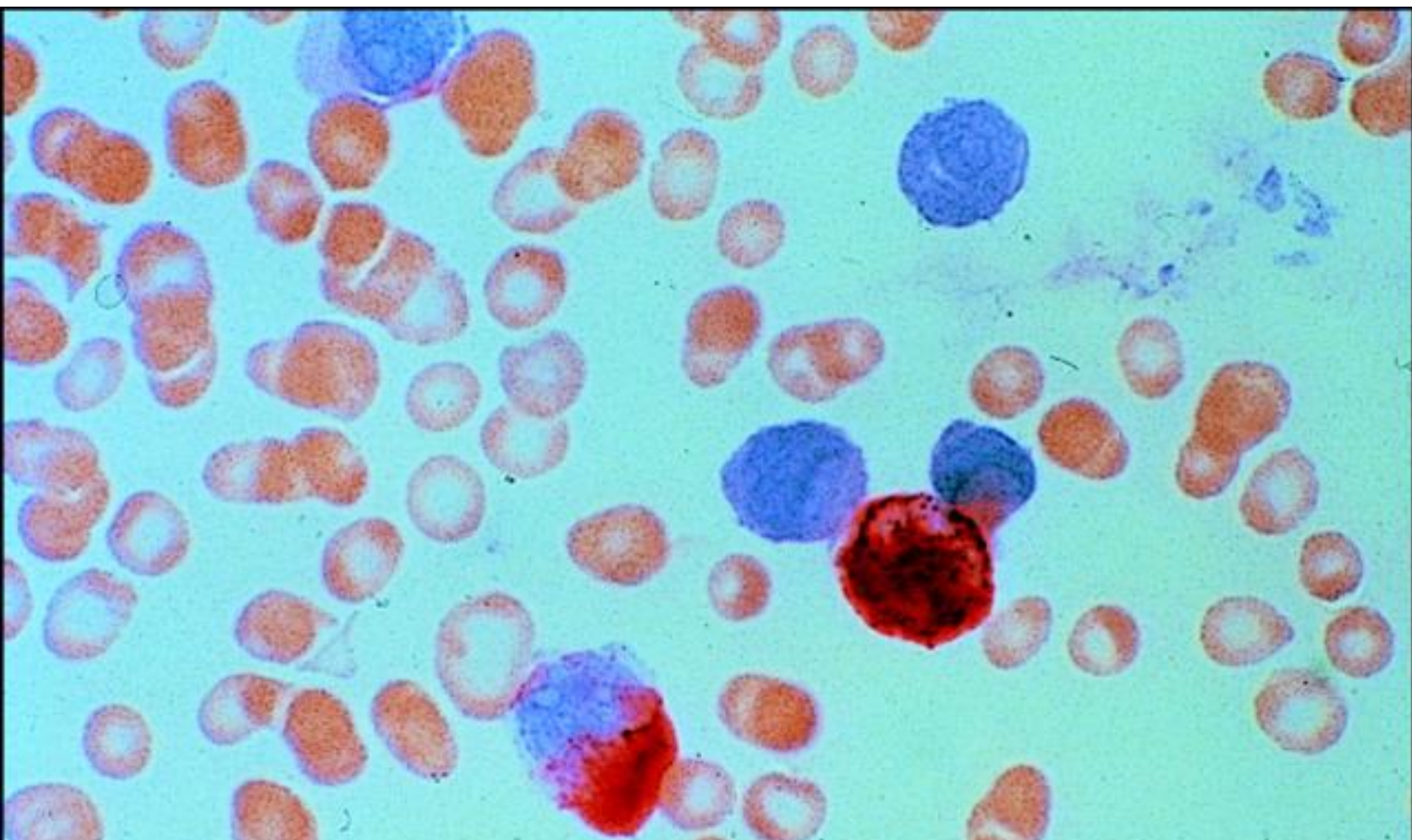
Demonstrates/highlights basement membrane in renal glomerules





Von Kossa stain:

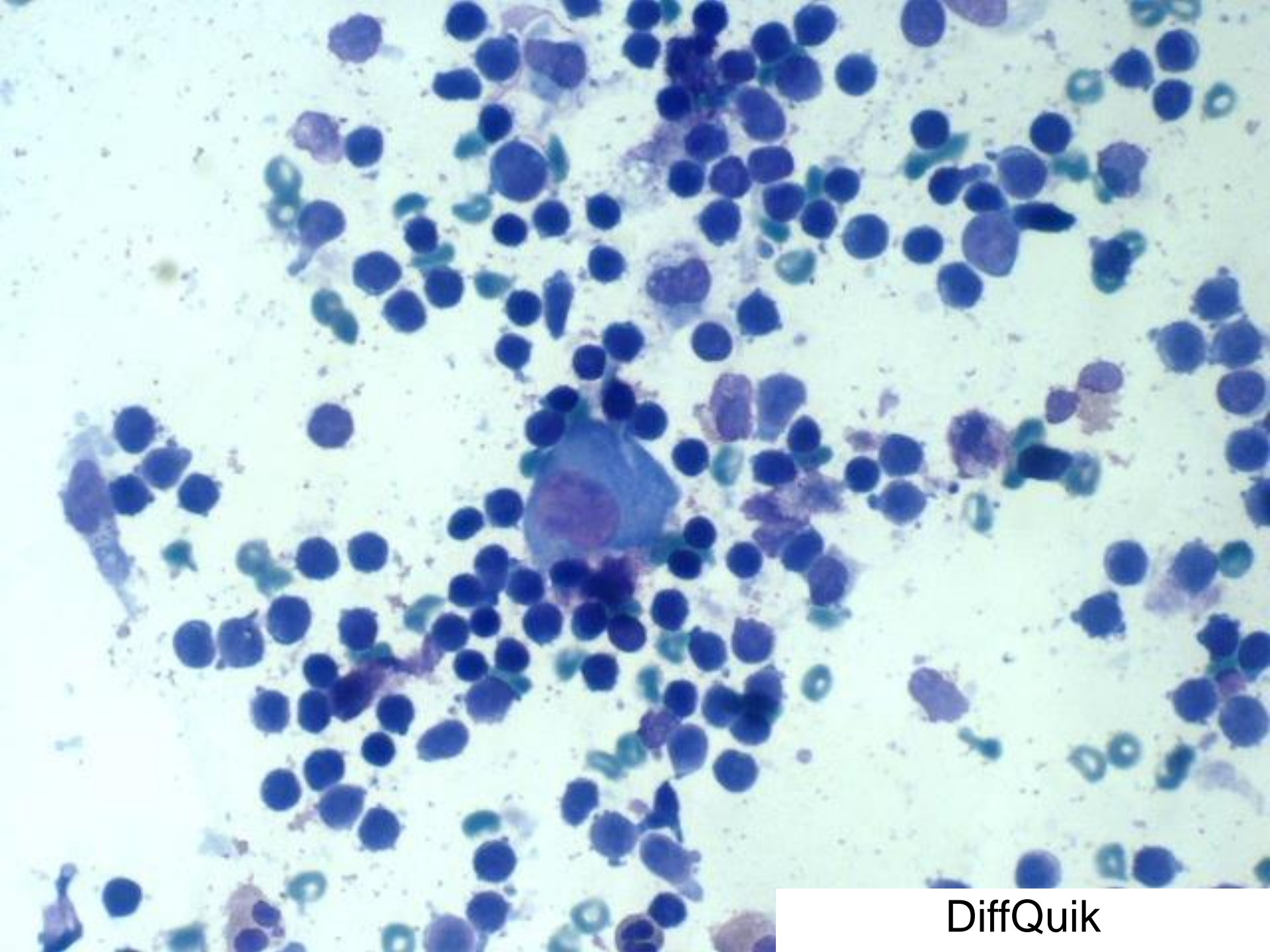Stains Ca^{++} (appears deep-blue to purple); identifies mineralization within tissues



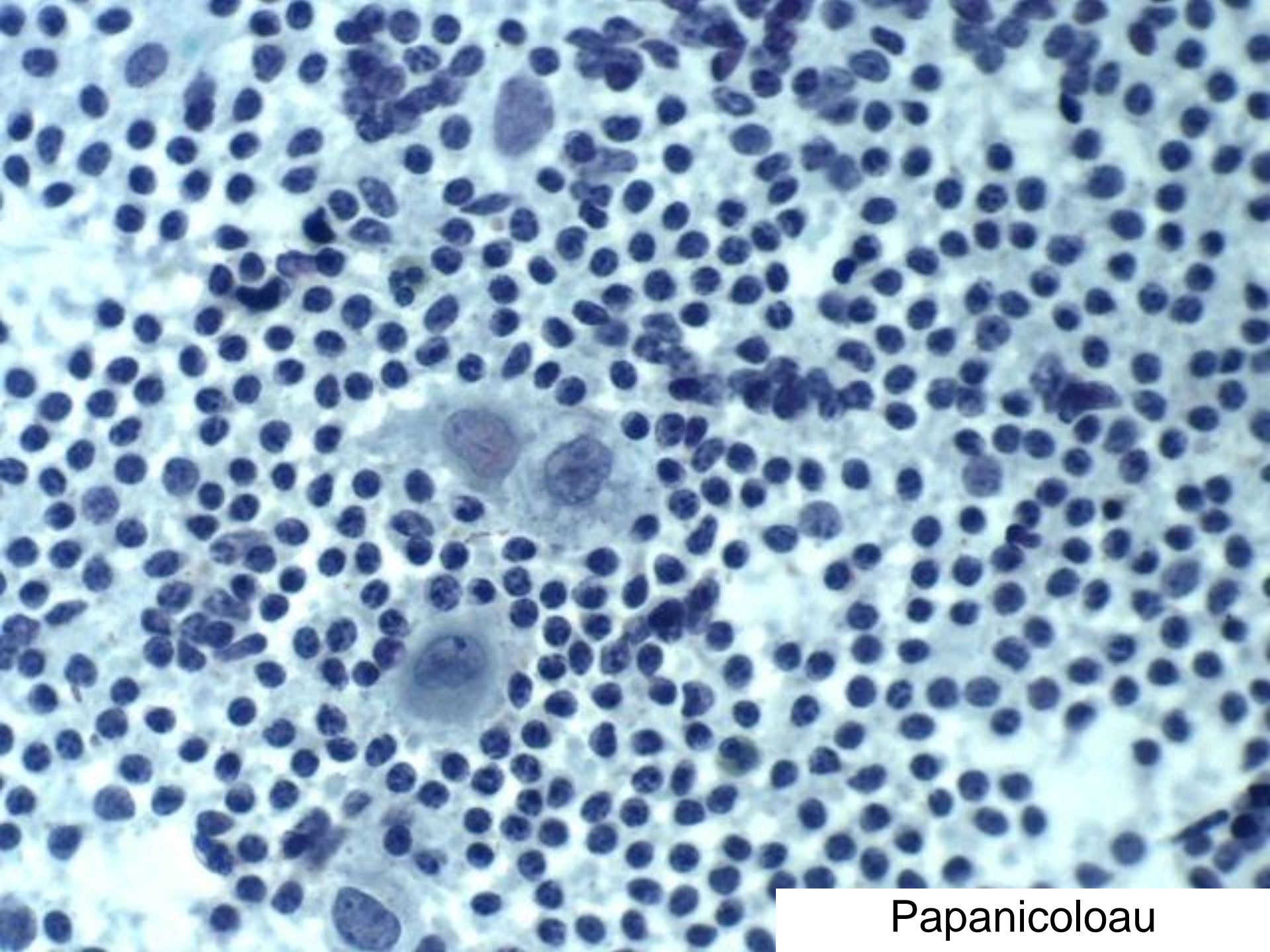Leder stain:

Detects the enzyme *chloracetate esterase* found in granulocytes, including mast cells; positive staining is seen in CLL vs. CML

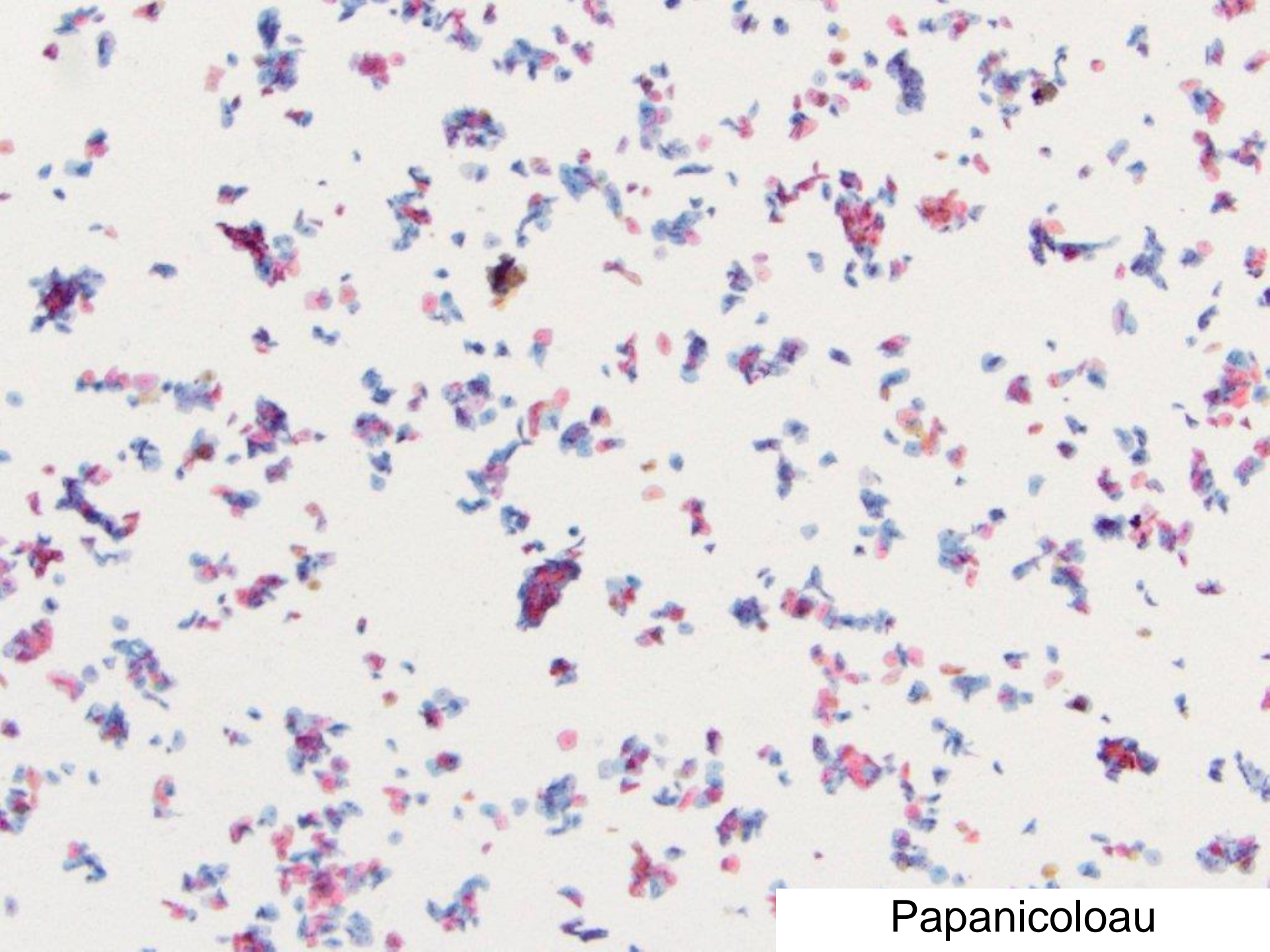
other stains



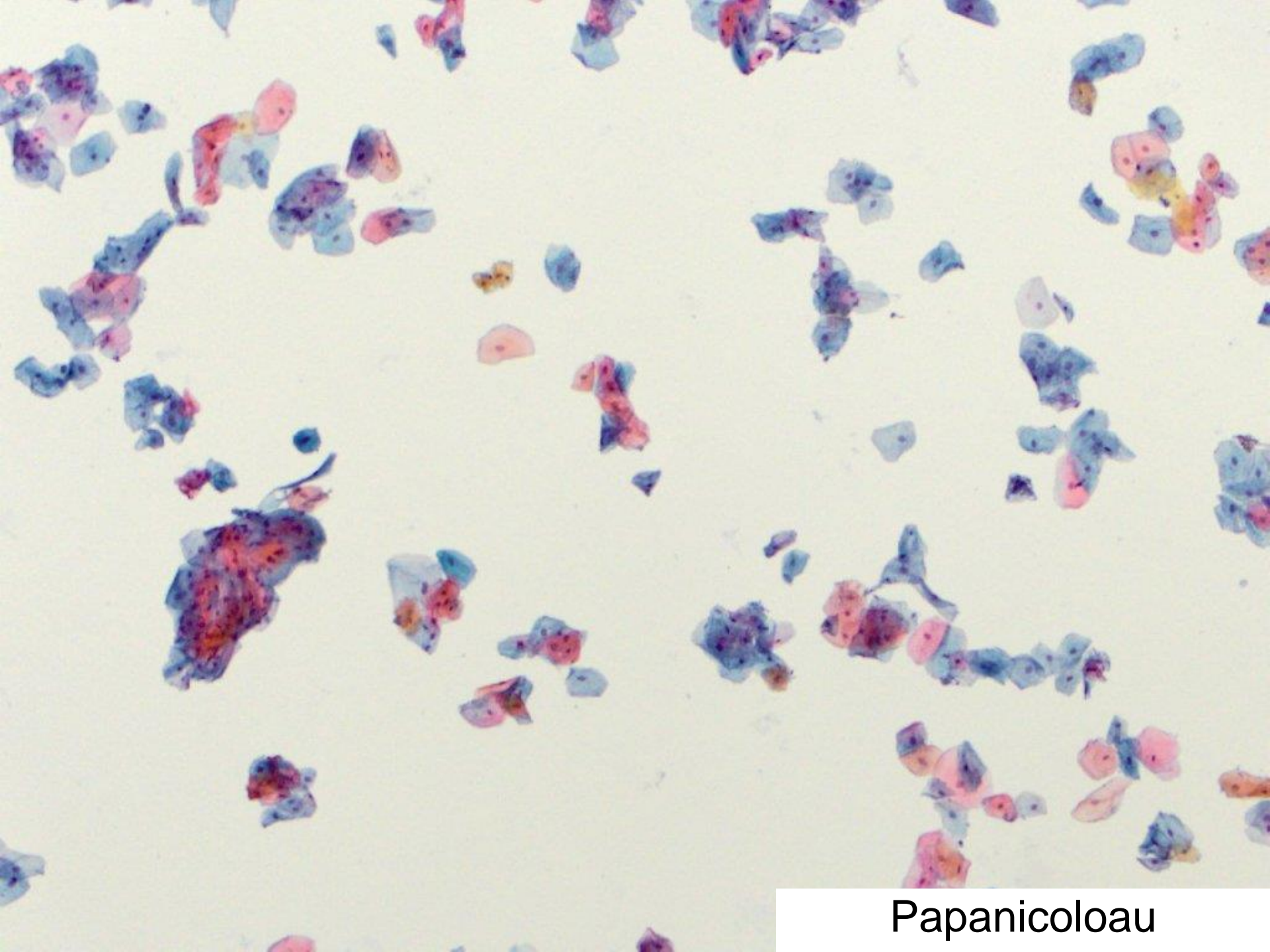
DiffQuik



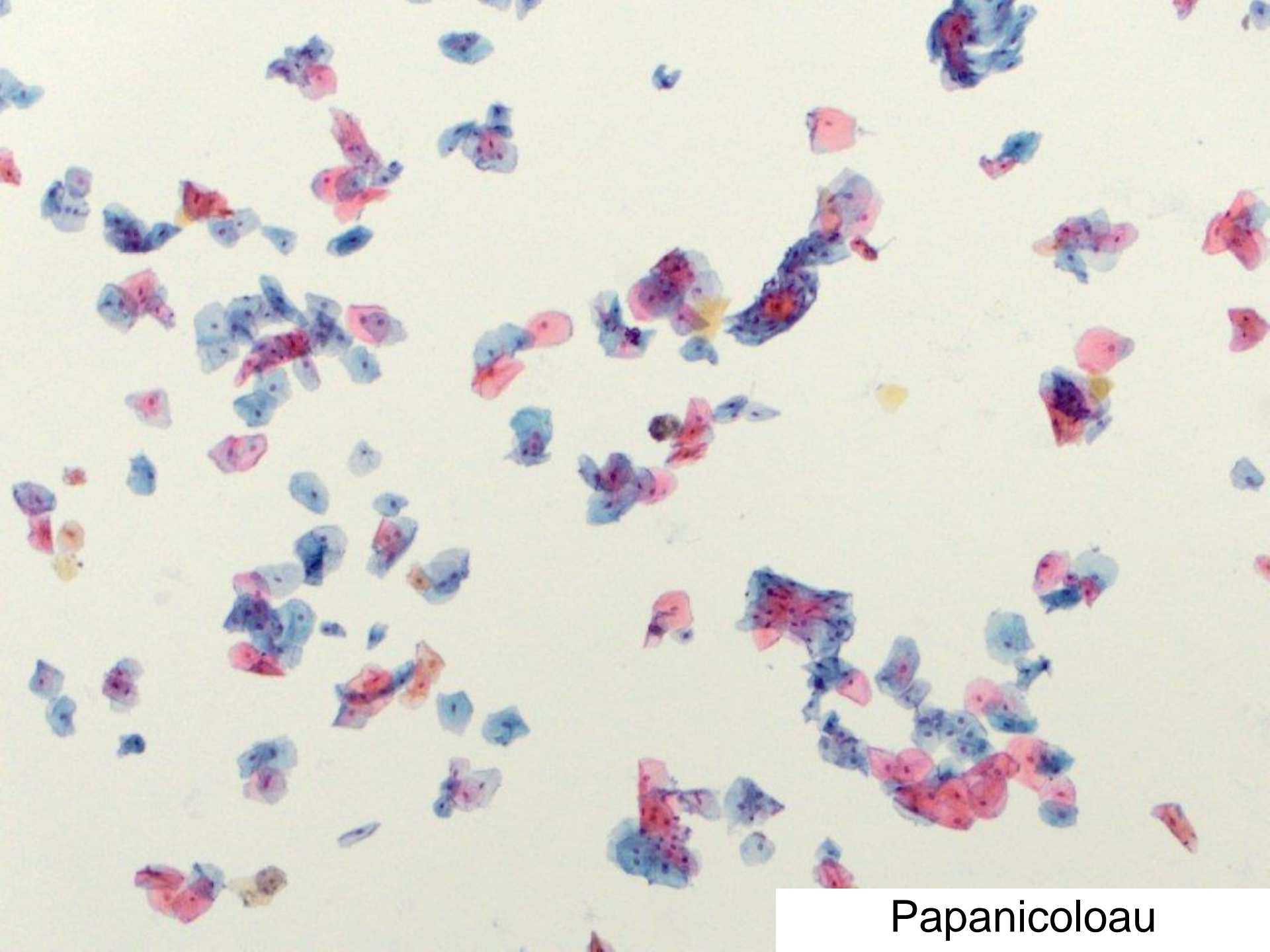
Papanicoloau



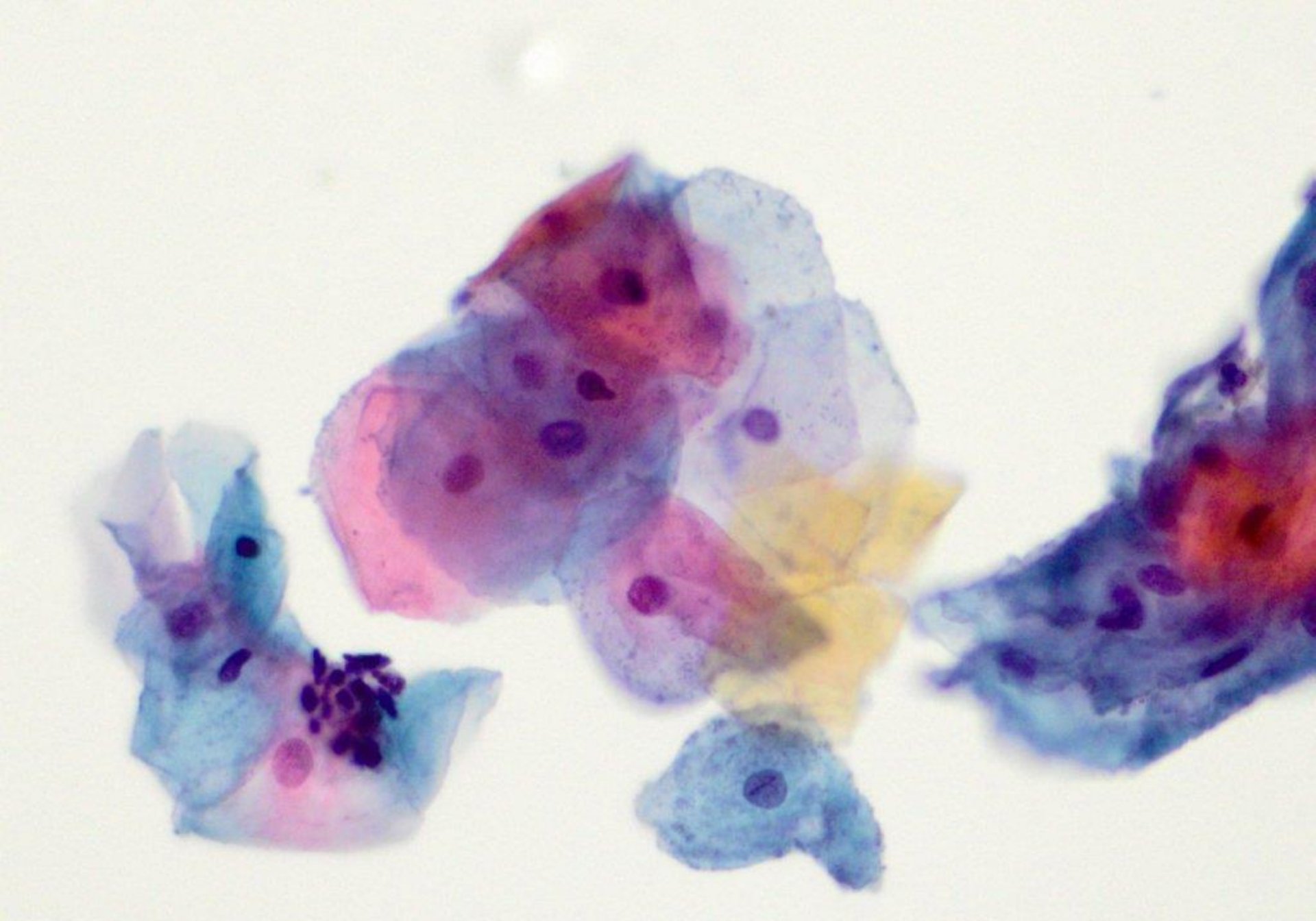
Papanicolaou



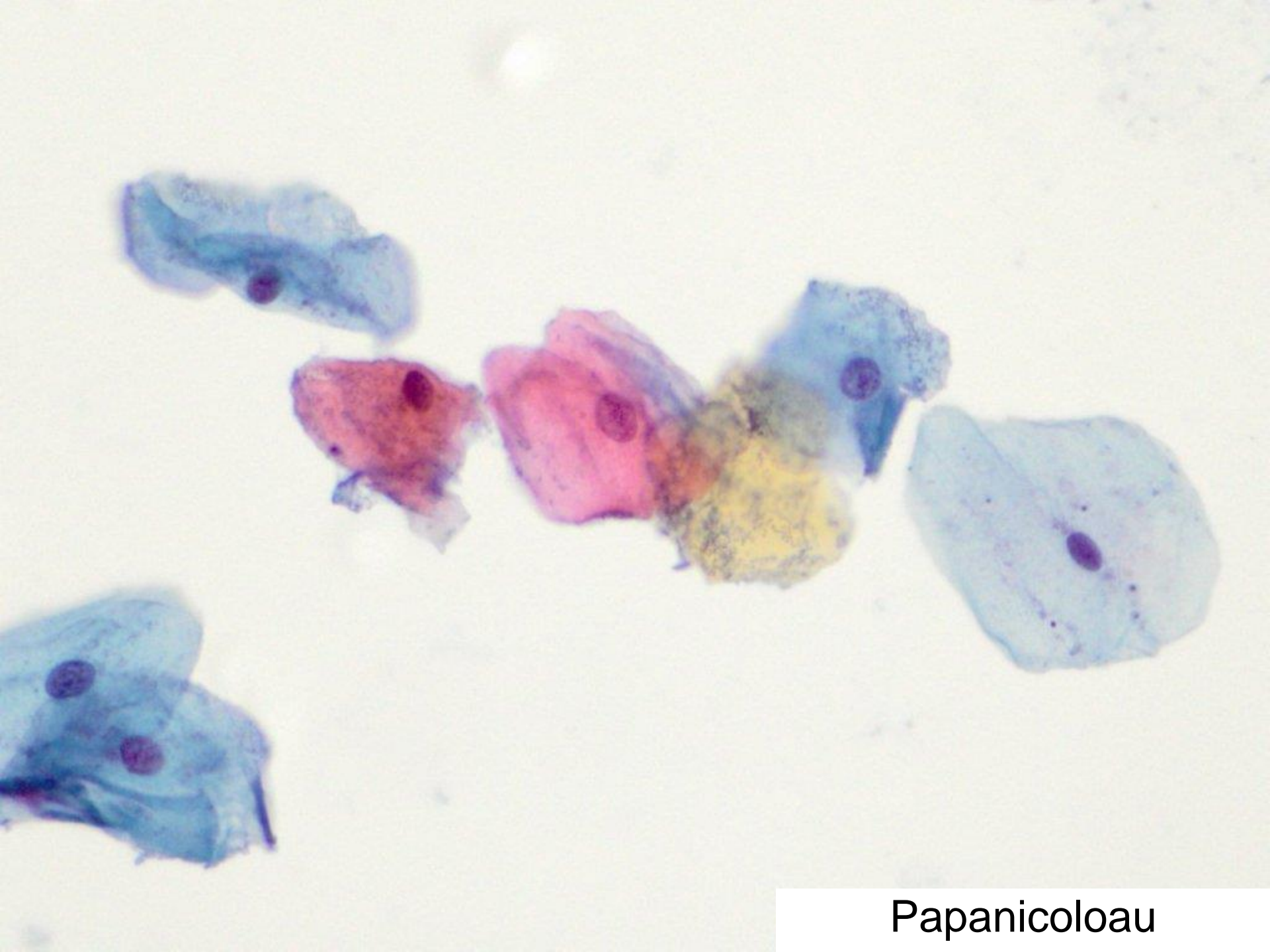
Papanicolaou



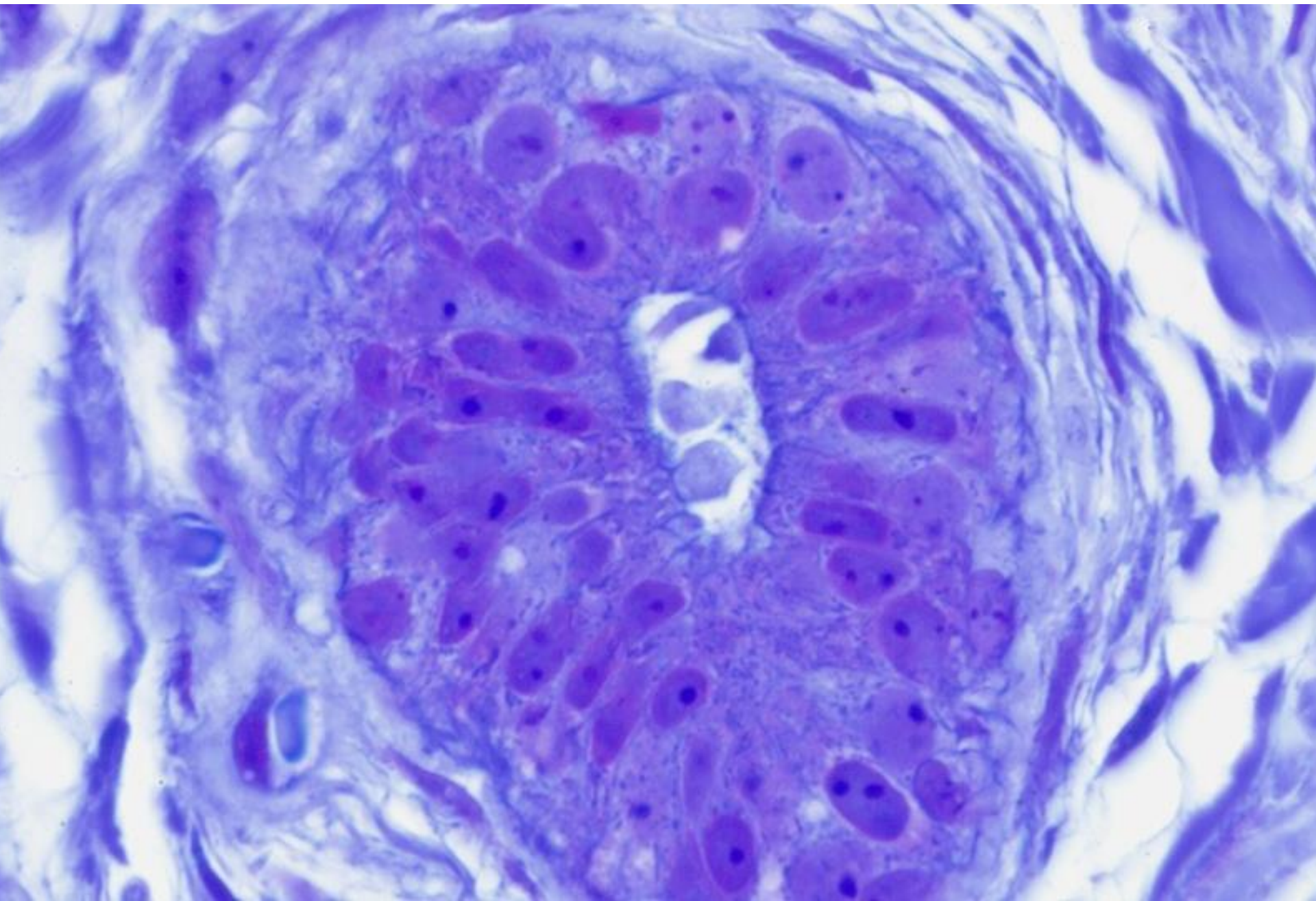
Papanicolaou



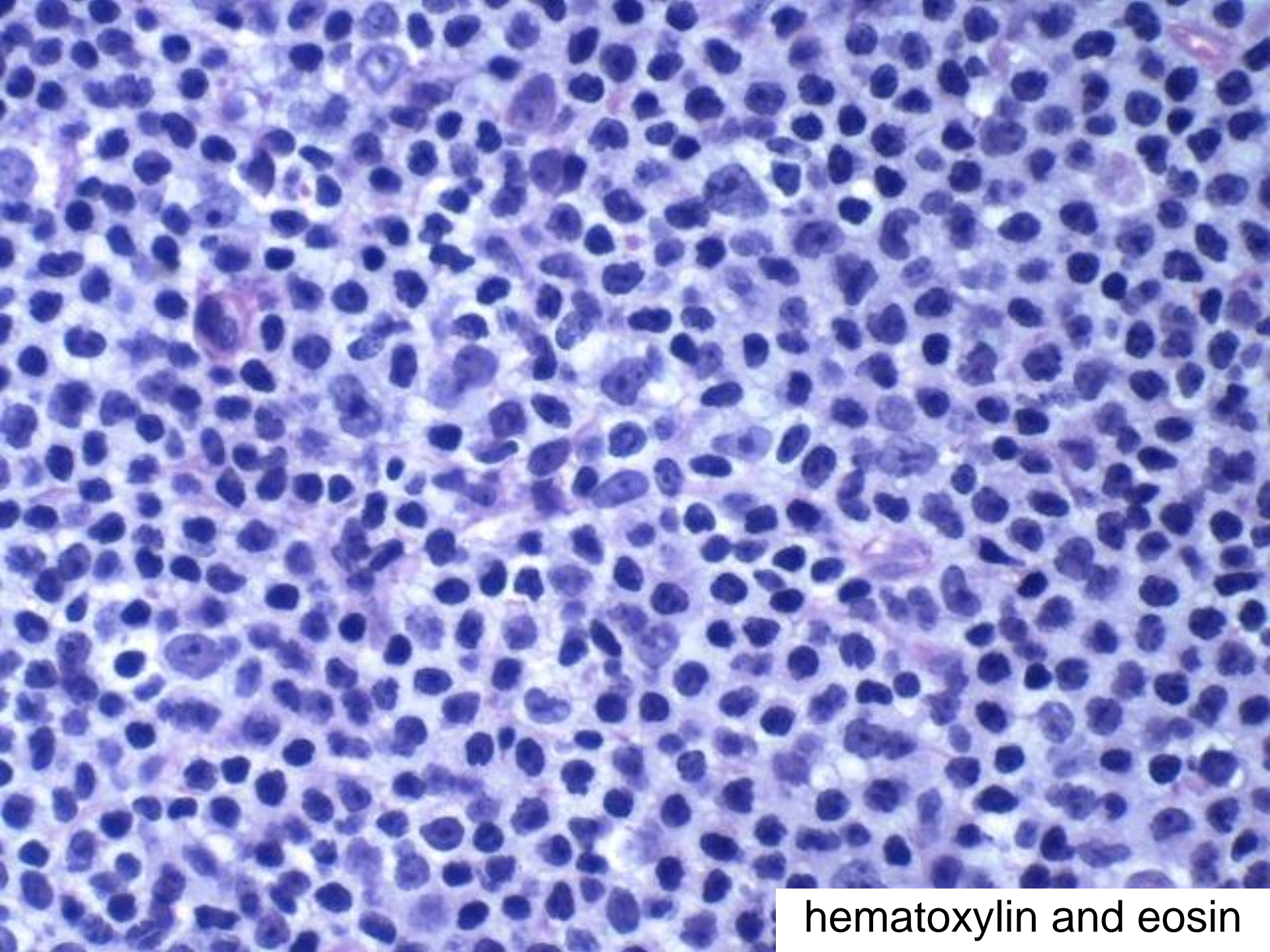
Papanicolaou



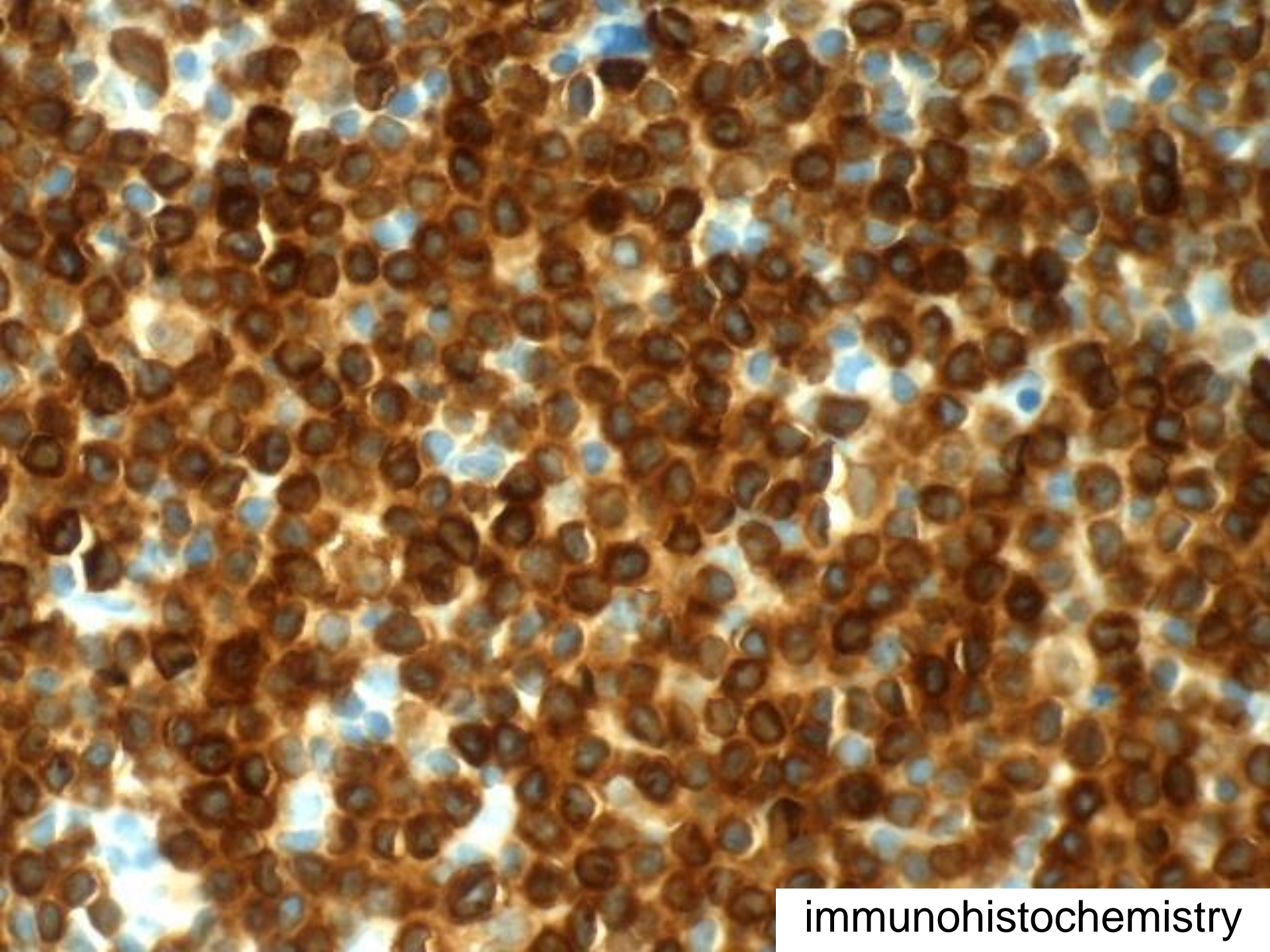
Papanicolaou



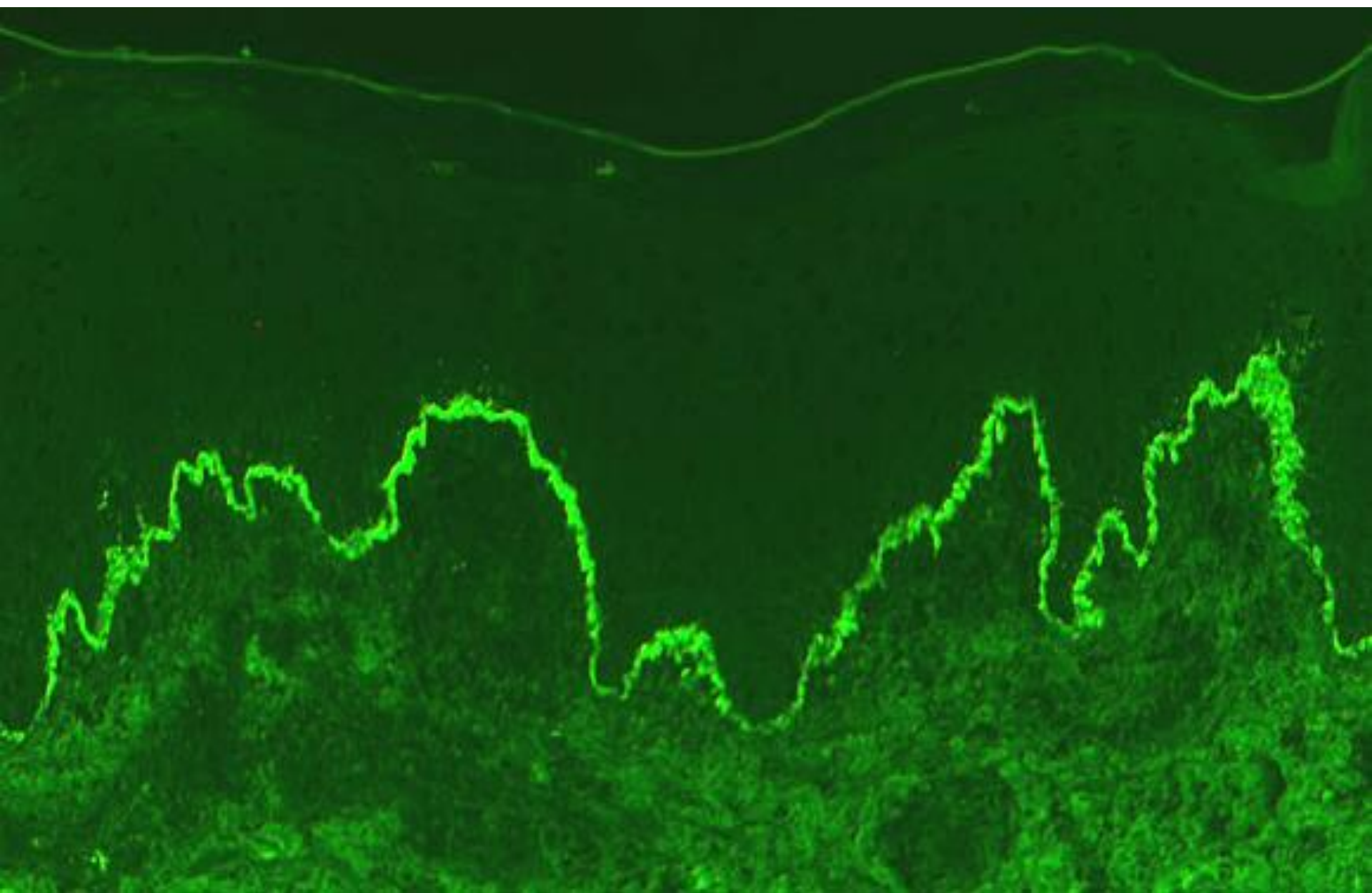
toluidine blue



hematoxylin and eosin



immunohistochemistry



immunofluorescence